

Romeo T. Cristina^{1*}, Eugenia Dumitrescu¹, Diana Brezovan², Florin Muselin³
Viorica Chiurciu⁴

¹Pharmacology and Pharmacy Dept., USAMVB, Faculty of Veterinary Medicine, 119, Calea Aradului, Timișoara, Romania; ²Histology and Molecular biology Dept., USAMVB, Faculty of Veterinary Medicine, 119, Calea Aradului, Timișoara, Romania; ³Botany Dept., USAMVB, Faculty of Veterinary Medicine, 119, Calea Aradului, Timișoara, Romania; ⁴Drugs Production Dept., Romvac Company, Șos. Centurii no. 7, Voluntari, Romania.

*Email: rtcristina@yahoo.com

Abstract

Background: A pharmaco-chemical investigation of the *Euphorbia cyparissias* plant was justified by its known multiple therapeutic valences. Numerous components from extracts and latex of Euphorbiaceae were identified, revealing a large plant family with a polyvalent therapeutic activity.

Materials and Methods: The aim of the study was to assess the skin tolerance level to irritation on different testing concentrations, of *Euphorbia cyparissias* extracts and ointments. Study was accomplished in rats and dogs, with the identification of all possible skin injuries and histological changes, after a simple patch test methodology.

Results: Ointment dermatological testing on rats, proved to be bearable on epilated skin at concentrations of 1, 2 and 5%. Ointments and mother tincture with higher concentrations (10% and 20%), led to irritation and cutis damages, and this was revealed through histology.

Conclusion: Ointment tested on dog's skin was tolerable for epilated skin to concentrations of 1, 2 and/or 5%, additional testing on human volunteers confirmed the same situation.

Key words: Acanthosis, *Euphorbia cyparissias*, ointments, rat, dog, dermatology test

Introduction

In modern human and veterinary therapeutics, the concept of biotherapy has become more frequent. In this context, researchers from all over the world are seeking to align, and to bring new information in relation to the use of plants from the spontaneous flora as well as other modern means in the anti-parasitic arsenal (Madzimure et al., 2011; Sanis et al., 2012; Samish and Rehacek, 1999; Santhoshkumar et al., 2012; Webb and David, 2002). The preoccupations linked to the parasites' control and bio-control models (Barci, 1997; Jongejan and Uilenberg, 1994; Kaaya, 2003), have diversified, numerous new fight means like: fungus (Kaaya, 1996), entomogenous nematodes (Kaaya et al., 2000; Samish and Glazer, 1991), vegetal extracts (Borges et al., 2003; De Souza Chagas et al., 2012; Schwalbach et al., 2003), volatile oils (Iori et al., 2005; Ismail et al., 2002; Kim et al., 2004; Walton et al., 2004) and other, being studied.

Numerous components from extracts and latex of Euphorbiaceae were identified, mostly diterpenes: phorbol ester (ingenole), euphorbone, piceatanole, aesculetine, jolkinol, hyperoside, kaempferol, acylphorbol, acylingenol etc. (Ahmad and Jassbi, 1999; Evanics et al., 2001; Ferreira et al., 1993). Pharmaco-chemical investigation of the Euphorbiaceae family is justified by its known multiple therapeutic valences (Özbilgin and Saltan Citoğlu, 2012; Tabuti, 2008). Numbering over 3000, species, this large plant family is a polyvalent one from a medicinal point of view: with cancer studied efficiency (Wang et al., 2012), homeopathic (Garcia et al., 2010), anti-inflammatory (Singh et al., 1984), insecticidal (Zahir and Rahuman, 2012), repellent (Ogunlesi et al., 2009), antiviral (Akihisa et al., 2002), diuretic (Ashok et al., 2011) and many others (Shih and Cherng, 2012).

The aim was to assess the skin tolerance to irritation on different testing concentrations, of *Euphorbia cyparissias* extracts and ointments, in laboratory rats and dog, with the identification of all possible skin injuries and histological changes, registering, after a simple patch test methodology, as a preliminary step in conception of a final formulation, a specific ointment with *E. cyparissias* extract.

Materials and Methods

Euphorbia ointment and dilutions preparation

Euphorbia cyparissias was collected from Banat region, Western Romania (plant's identification and authentication was made; plant being compared with a herbarium specimen (voucher no. 41), from the collection of Vegetal Biology and Medicinal Plants Department from FVM Timisoara, Romania.

Plant extracts were obtained according to Romanian Pharmacopeia, Xth Ed. (1993), instructions at *Tincturae* or *Unguenta* monographs. 100 ml *E. cyparissias*, 20% mother tincture previously obtained was evaporated and concentrated on marine bath. Over it, 50 g ointment base was added progressively, mixing continuously for 20 minutes, until total tincture's embedding in the ointment mass. After homogenisation the hot ointment was poured in plastic boxes, eliminating oxygen bubbles and left to stand for 60 minutes, so being obtained a prime 10% *E. cyparissias* ointment.

The used ointment base, Ultrabasic cream (Ratiopharm GmbH, Germany), was an amphiphilic complex basis adjusted to pH = 5, choosing of this ointment base being precisely recommended, due to its good incorporating features of the vegetal complex compositions, tannins, latex, oils etc. For this reason, this base was considered ideal for skin topical applications, being well tolerated and forming uniform films on skin. Hot 10% ointment was then successively diluted in the following proportions: 1:1 (w/w) to obtain concentration of 5%; 1: 2.5 (w/w) to a concentration of 2% and respectively; 1:1 (w/w) to concentration of 1%.

<http://dx.doi.org/10.4314/ajtcam.v11i3.1>

As initial testing before the patch test, the mother *E. cyparissias* tincture 20% concentration (considered by us as the maximum therapeutic concentration in animals) it was used only on rats, in the aim to see if there are any changes that may occur in cutis structure, Application of the *E. cyparissias* ointments was accomplished with protected hand, avoiding the contact with eyelid mucous.

Patch-test methodology

The test was performed accordingly to a simple *patch test method* protocols, accepted in dermatology, both for rats and dog. During testing, all major local and general side effects: the degree and nature of irritation, mother tincture and ointment's corrosivity, reversibility of installed damages and any other local or general toxic effect (Ale and Maibach, 2010; DermNet NZ, 2012; Spiewak, 2008). In Table 1, animals used and methodology are presented.

Table 1: Animals' used and simple patch-test methodology

Rats	12; clinically healthy animals, three / concentration.
Dog	Clinically healthy animal, the ointment concentrations were applied consequently on abdominal region in different epilated areas.
Human volunteer	Consequently 1, 2, and 5% ointments were applied on the arm and lid. In the case of palbebral topical applications, ointments were applied on eyelids as follows: right upper eyelid 1%, lower left eyelid 2% above 5%.
Control lot	Not necessary
Preliminary test	Ointment's pH values assessment (not allowed if the substance has a $\text{pH} \leq 2$ or ≥ 11.5)
Skin preparing	Hair removal 24 hours before testing without skin lesions, followed by light scarification
Application area	4 cm ² (2/2 cm)
Dressing	Gauze bandage soaked in ointment and fixed with adhesive bandage
Exposure time	30 minutes
Number of applications	One
Skin reaction monitoring after application at	30 min., 8, 24, 36 and 48 h

Skin reaction assessing was done after classical scoring by grades from 0 to 4, final quantification of sensitivity testing being based on average mark of the subjects included in the study (Table 2).

Table 2: Evaluation of skin reaction after skin applications

Classification of reactions identified consecutive exposures	Category	Average
no visible reaction, possibly slight desquamation	Bearable pain	0 – 0.99
slight congestion which disappeared after 24 hours		
congestion and inflammation which decreases in 36 hours	Average affordability	1.0 – 2.79
congestion and inflammation which not decreases in 36 hours	Irritant	2.80 – 3.69
congestion and pustules lymph extravasations, prolonged healing time of 48 hours	Severe irritant	3.70 – 4.0

Histological investigation

Skin samples

Samples were collected from rats euthanized in the respect of current standards of ethics in scientific research. Rats were euthanized in accordance with European Directive 2010/63/EU from 09/22/2010. Euthanasia method used was that by overdosing anesthetic agents using the association: Ketamine (Intervet, Boxmeere, The Netherlands) (300 mgkg⁻¹bw) and xylazine Narcoxyl 2 (Xylazine, MSD Animal Health, Boxmeere, The Netherlands) 30 mgkg⁻¹bw, i.e. 0.3 ml ketamine + 0.15 ml xylazine /100gkg⁻¹bw, by I.P. or S.C. way, in accordance with existing own institutional bioethical and all performed procedures (CETS No.: 123, 1986; Directive 2010/63/EU; SVH AEC SOP.26, 2006).

Skin flaps from rats were placed in 5% formalin solution for histological processing (Şincai, 2000). From dog the skin samples were collected surgically and places were sanitized and coated with protective sulphonamide powder, to avoid any local infections.

Staining method

The method used for rat skin was haematoxylin-eosin (col. H & E). For coloration of dog skin samples, trichromic Mallory staining was used (col. TRC), which contains acid fuchsine solution, phosphomolybdate acid solution and Mallory mix, being a specific staining for conjunctive tissue, nuclei and fibres (Şincai, 2000), microscopy being performed to the Olympus CX 41 (*Olympus, GmbH Germany*), equipped with a camera, to the objective x 200 (H&E), and of x 400 (col. TRC).

<http://dx.doi.org/10.4314/ajtcam.v11i3.1>

Results and Discussion

Tested ointment proved to be bearable on rats' epilated skin at concentrations of 1, 2, and / or 5% (Table 3). Contact of rats skin with high concentrations ointment (10%), led to reduced and short term irritation of the cutis and caused reactions includable in skin tolerance Class I = *medium irritating*. When mother tincture (20%) was used, detected changes were characteristic to category SI = *strong irritant* reactions, due to irritating action, situation also revealed by the histological examination (Figures 1 to 6).

Table 3: Assessment of coetaneous tolerance of *E. cyparissias* ointment in rat

Concentration	No.	Irritation Quantification	Reaction's classification
		Average	
20%	3	3	Irritant
10%	3	1	Average affordability
5%	3	0,66	Supportable irritant
2%	3	0,33	Supportable non-irritant

Histological

To concentrations inferior to 20%, were not identified significant histological changes. The main changes identified were: thickening of the epidermis, especially of the *stratum corneum*, keratinocytes vacuolar degeneration, small areas damage of *lamina basalis*, who separates the epidermis and papillary dermis and occurrence of cells specific to dermal inflammatory process (only at concentrations of 10% and especially to 20%) (Figures 1 to 6).




Figure 1: Histologic examination of the skin treated with *E. cyparissias* 1% ointment (col. H&E x 200). (all color figures have resolution of 300 dpi).

Histological sections revealed that the epidermis has a normal appearance with multi-layered intact epithelium, where there are vacuolated keratinocytes but in reduced proportion (**red**). Skin thickness is maintained within normal limits. In the dermis were revealed very few inflammatory cells (**orange**). Also glandular structures (in particular, the sebaceous gland (**blue**) corneous formations (hair) do not show significant changes.

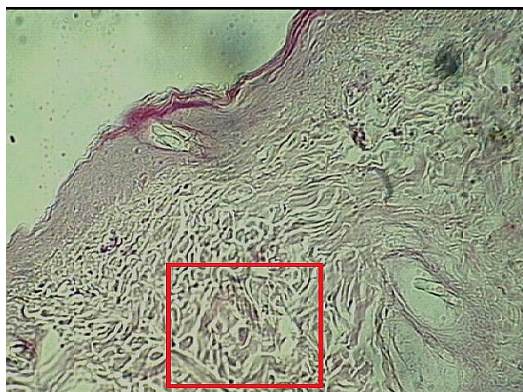

Figure 2: Histologic examination of the skin treated with the ointment of *E. cyparissias* at a concentration of 2% (Col. H&E x 200).

Histologic examination of the skin did not highlighted major changes. Epidermis showed no structural changes or of thickness but compared with group 1% it was found an increased number of inflammatory type cells (**red**).

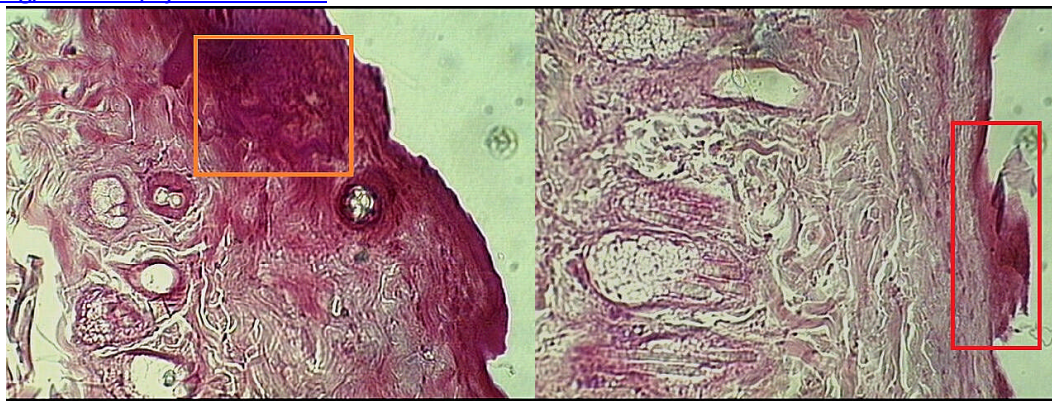

Figure 3. (Col. H&E x 200)

Figure 4. (Col. H&E. x 200)

Figure 3 and Figure 4. Histologic examination of the skin that was applied with 5 (fig. 3) and 10% (fig. 4) ointment concentrations (Col. H&E x 200).

Histologic examination of the skin that was applied with 5 (fig. 3) and 10% (fig. 4) ointment concentrations (col. H&E x 200)

Histologic examination of the skin showed for both concentrations, but especially for the higher one, development of the contact dermatitis phenomena. Diskeratosi, hypo- or parakeratosi (**orange**) it was observed also altered *membrana basalis* and circumscribed cellular infiltrations in dermis were observed, as the occurrence of specific inflammatory process (**red**).

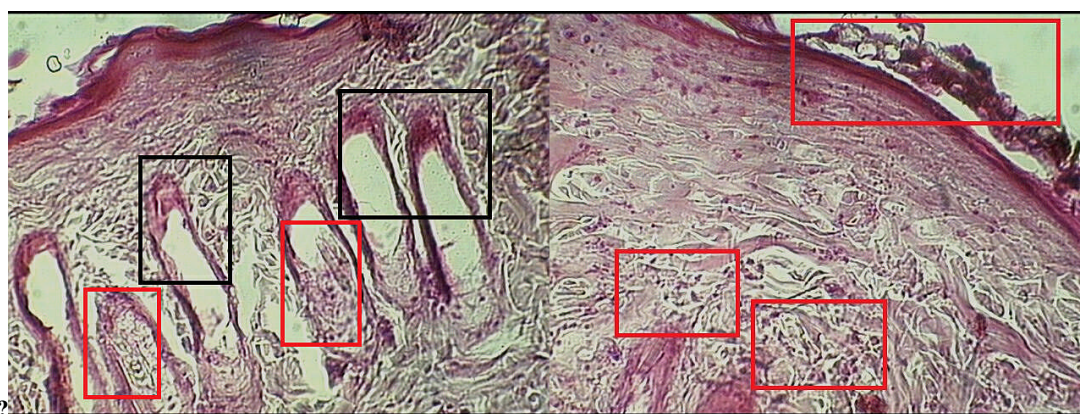


Figure 5. (Col. H&E x 200)

Figure 6. (Col. H&E x 200)

Histologic examination of the skin treated with *E. cyparissias* mother tincture (20%)

Figure 5 and Figure 6. Histologic examination of the skin treated with *E. cyparissias* mother tincture (20%)

Histologic examination of the skin showed worsening of contact dermatitis. In addition, most of the sebaceous glands necrosis in various stages from partial (**red**) to complete (**black**) of secretor and basal proliferative cells, which become flattened. Alveolar sacs are empty of cells and by its secretion product. These aspects indicate severe reduction in functional capacity of the sebaceous gland (fig.5). Thus, the sebum quantity secreted are greatly diminished, a phenomenon that explains the dry and brittle skin in case of concentrated ointments using. In the dermis massive cellular infiltration was observed, specific to inflammatory processes (**red**) (Figure.6).

Dermatological testing in dog

Evaluation of coetaneous tolerance for ointments was followed on a Cocker spaniel dog. Testing showed total non-irritant character of 1%, 2% ointment concentrations, not being identified any local or general reactions. In the case of 5% concentration, only light coetaneous reactions, reported tolerance values being includable in B = *bearable* category of acanthosis.

Histological

The main histological changes were observed in skin structure only after applying *E. cyparissias* ointment with concentration of 5% and there were: thickening of the epidermis, especially of *stratum corneum*, keratinocytes' vacuolar degeneration, destruction of small portions of *lamina basalis*, specific for the dermal inflammatory process (for 5% ointment). It is to note that at lower concentrations weren't identified any significant histological changes (Figures 7 and 8).

<http://dx.doi.org/10.4314/ajtcam.v11i3.1>

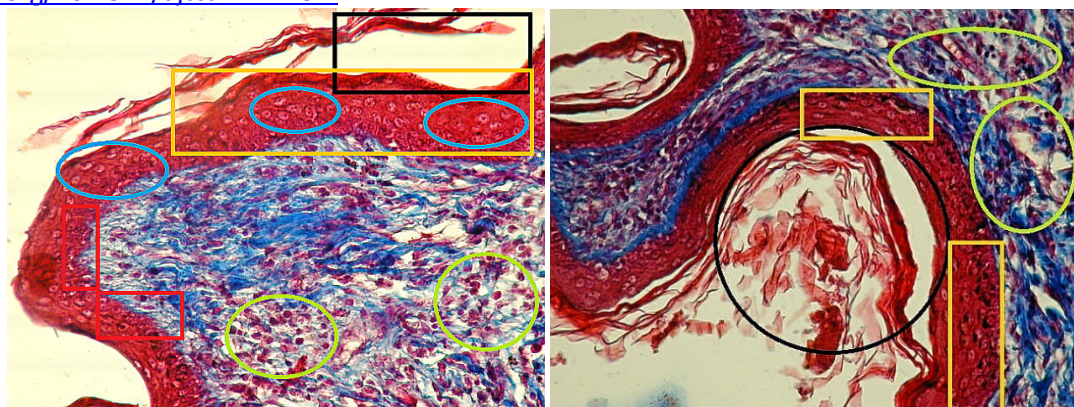


Figure 7. (Col. TRC x 400)

Figure 8. (Col. TRC x 400)

Figures 7 and 8: Sections made through the dog's skin consecutive applications of 5% *E cyparissias* ointment concentration (Col. TRC x 400)
Section made through the dog's skin consecutive applications of 5% *E cyparissias* ointment concentration (col. TRC x 400)

Thickening of epidermis (**orange**); skin peeling (**black**); vacuolar degeneration of keratinocytes (**blue**); destruction of *lamina basalis* (**red**); cell proliferation in the dermis, specific to inflammatory process (**green**).

Dermatologic observations on human volunteer

Applications on arm' skin did not cause any irritation, discoloration or volume modification at any of the studied concentrations. In the case of palbebral topical applications, ointments were applied on eyelids as follows: right upper eyelid 1%, lower left eyelid 2% above 5%. After 3-8 hours after ointments application, subject felt a diffuse burning irritation only after applying ointment with concentration of 5%. Irritation was felt only to the correspondent lid (top left). After 8 hours after application, sore diminished, but the complete recovery after swelling of the eyelids was observed only at 24 hours after application. Edema was persistent yet after 48 hours of application, but it was not accompanied by pain or other event. Accordingly to our estimation methodology, recorded effects can be included in average affordability (1 to 2.79).

Studies made by our research team about the active compounds of *Euphorbia cyparissias* (*Cypress spurge*) as well as their activity *in vivo* and *in vitro* revealed additional significant ectoparasitic activity, especially against argasides and dog's demodectic mange (Cristina et al., 2008). Present testing occurred due to the need to further studies of the above-mentioned compounds activity in demodicosis, a zoonotic skin parasitic disease frequent in dogs and enough spread in humans, where the ointment was originally used by us and where acanthosis studies are needed (Lachapelle and Maibach, 2012, EAHC, 2009; Spiewak, 2008).

Conclusions

Euphorbia cyparissias ointment dermatologically tested on rats, proved to be bearable on epilated skin at concentrations of 1, 2 and 5%. Ointments and mother tincture with higher concentrations (10% and 20%) led to irritation and cutis damages, histologically revealed. Ointment tested on dog's cutis appears to be tolerable for epilated skin to concentrations of 1, 2 and/or 5%. However, to the contact with epilated skin of ointments with concentration of 5%, can register very small and short term irritation of the cutis, which can be considered therapeutically negligible, histological examination revealing this situation. *Euphorbia cyparissias* ointment can be used in veterinary therapy at the concentrations of 2 and 5% without encountering difficulty, ointments at this concentration being included in the bearable non-irritant category. Application of *E. cyparissias* ointments should be made with protected hand, avoiding the contact with mucous eyelid.

Acknowledgment

The work was supported by The National University Research Council (NURC) of Romania, from Type A, Multianual Grant, No. 6/999.

References

- Ahmad, V.U., and Jassbi, A.R. (1999). New diterpenoids from *Euphorbia teheranica*. J Nat Prod. 62: 1016-1018.
- Akihisa, T., Kithsirir, W.E., Tokuda, H., Enjo, F., Toriumi, M., Kimura, Y., Koike, K., Nikaido, T., Tezuka, Y., and Nishino (2002). *H. Eupha*, 7, 9 (11), 24-trien-3beta-ol ("*antiquol C*") and other triterpenes from *Euphorbia antiquorum* latex and their inhibitory effects on Epstein-Barr virus activation. J Nat Prod. 65(2): 158-162.
- Ale, I.S., and Maibach, H.A. (2010). Diagnostic Approach in Allergic and Irritant Contact Dermatitis Expert Rev Clin Immunol, 6(2): 291-310.
- Ashok, B.K., Bhat, S.D., Shukla, V.J., and Ravishankar, B. (2011). Ayu, 32(3): 385-387.
- Ayyanar, M., and Ignacimuthu, S. (2009). Herbal medicines for wound healing among tribal people in Southern India: Ethnobotanical and Scientific evidences. IJARNP, 2(3): 29-42. <http://ijarnp.org/index.php/ijarnp/article/view/46/47>
- Barci, L.A.G. (1997). Biological control of the cattle *Boophilus microplus* (Acari: Ixodidae) in Brazil. Arg Inst Biol, 64: 95-101.
- Borges, L.M.F., Ferri, P.H., Silva, W.J., Silva, W.C., and Silva, J.G. (2003). *In vitro* efficacy of extracts of *Melia azedarach* against the tick *Boophilus microplus*. Med Vet Entomol, 17: 228-231.
- CETS No. 123 (1986). European Convention for the Protection of Vertebrate Animals used for Experimental and Other Scientific Purposes, Council of Europe, Strasbourg. <http://conventions.coe.int/treaty/en/treaties/html/123.htm>

<http://dx.doi.org/10.4314/ajtcam.v11i3.1>

9. Cristina, R.T., Cosoroabă, J., Trif, A., Pârvu, D., Hădărugă, N., Dumitrescu, E., Argherie, D., and Costescu, C. (2008). Investigation on *Cypripedium* (*Euphorbia cyparissias* L.) and its activity in the veterinary therapeutics. International Conference of cellular and tissue comparative pathology, July 3-5, 2008, Cluj Napoca. Bull USAMV-CN, 65(1-2): 358-363.
10. De Souza Chagas, A.C., De Barros, L.D., Cotinguiba, F., Furlan, M., Giglioti, R., De Sena, O.M.C., and Bizzo, H.R. (2012). *In vitro* efficacy of plant extracts and synthesized substances on *Rhipicephalus (Boophilus) microplus (Acari: Ixodidae)*. Parasitol Res, 110(1): 295-303.
11. DermNet, N.Z. The New Zealand Dermatological Society (2012). Procedures to treat the skin - Patch tests (contact allergy testing) <http://dermnetnz.org/procedures/>
12. Directive 2010/63/EU of the European Parliament and of the Council on the protection of animals used for scientific purposes, 22 September 2010. Official Journal of the European Union 2010 L 276, 33-79 <http://eur-lex.europa.eu/LexUriServ/LexUriServ.do?uri=OJ:L:2010:276:0033:0079:en:PDF>
13. Evanics, F., Hohmann, J., Redei, D., Vasas, A., Gunther, G., and Dombi, G. (2001). New diterpene polyesters isolated from Hungarian *Euphorbia* species Acta Pharm Hung. 71(3):289-92.
14. Executive Agency for Health and Consumers (EAHC) (2009). The Critical Review of Methodologies and Approaches to Assess the Inherent Skin Sensitization Potential (skin allergies) of Chemicals (No 2009 61 04) http://ec.europa.eu/health/scientific_committees/docs/service_contract_20096104_en.pdf
15. Farmacopeea Română, Ediția a X-a, (1993). Ed. Medicală București (in Romanian).
16. Ferriera, M., Lobo, J.U., and Wyler, A.M. (1993). Triterpenes of *Euphorbia mellifera*. *Fitoterapia*, 64: 377.
17. Garcia, S., Harduim, R.C., Homsani, F., Zacharias, C.R., Ricardo Kuster, R.M., and Holandino, C. (2010). Physical chemical and cytotoxic evaluation of highly diluted solutions of *Euphorbia tirucalli* L. prepared through the fifty milesimal homeopathic method. Int J High Dilution Res, 9(31): 63-73.
18. Iori, A., Grazioli, D., Gentile, E., Marano, G., and Salvatore, G. (2005). Acaricidal properties of essential oil of *Meleuca alternifolia* Cheel (tea tree oil) against nymphs of *Ixodes ricinus*. Vet Parasitol, 129: 173-176.
19. Ismail, M.H., Ketavan, C., and Solomon, G. (2002). Toxic effect of Ethiopian neem oil on larvae of cattle tick, *Rhipicephalus pulchellus* Gerstaecker. Kasetsart J Nat Sci, 36(1): 18-22.
20. Jongejan, F., and Uilenberg, G. (1994). Ticks and control methods. Rev Sci tech Off Int Epiz, 13(4): 1201-1226.
21. Kaaya, G.P., Mwangi, E.N., and Ouna, E. (1996). Prospects for biological control of livestock ticks, *Rhipicephalus appendiculatus* and *Amblyomma variegatum* with the entomogenous fungi, *Beauveria bassiana* and *Metarhizium anisopliae*. J Invert Pathol, 67: 15-20.
22. Kaaya, G.P. (2003). Prospects for innovative methods of tick control in Africa. Insect Sci Applic, 23(1): 59-67.
23. Kaaya, G.P., Samish, M., and Itamar, G. (2000). Laboratory evaluation of pathogenicity of entomogenous nematodes to African tick species. Ann N Y Acad Sci, 916: 303-308.
24. Kim, S.I., Yi, J.H., Tak, J.H., and Ahn, Y.J. (2004). Acaricidal of plant essential oils against *Dermanyssus gallinae (Acari: Dermanyssidae)*. Vet Parasitol, 102: 297-304.
25. Lachapelle, J.M., and Maibach, H.I. (2012). A Practical Guide Official Publication of the ICDRG. Patch Testing Methodology, (Online) http://link.springer.com/chapter/10.1007/978-3-642-25492-5_3; 35-77.
26. Madzimure, J., Nyahangare, E.T., Hamudikuwan, D.H., Hove, T., Stevenson, P.C., Belmain, S.R., and Mvumi, B.M. (2011). Acaricidal efficacy against cattle ticks and acute oral toxicity of *Lippia javanica* (Burm F.) Spreng, Trop Anim Health Prod, 43: 481-489.
27. Ogunlesi, M., Okiei, W., Ofor, E., and Osibote, A.E. (2009). Analysis of the essential oil from the dried leaves of *Euphorbia hirta* Linn (*Euphorbiaceae*), a potential medication for asthma Afr J Biotechnol, 8(24): 7042-7050.
28. Özbilgin, S., Saltan Citoğlu, G. (2012). Uses of some *Euphorbia* species in traditional medicine in Turkey and their biological activities. Turk J Pharm Sci, 9(2): 241-256.
29. Samish, M., and Glazer, I. (1991). Killing ticks with parasitic nematodes of insects. J Invert Pathol, 58: 281-282.
30. Samish, M., and Rehacek, J. (1999). Pathogens and predators of ticks and their potential in biological control. Ann Rev Entomol, 44: 159-182.
31. Sanis, J., Ravindran, R., Ramankutty, S.A., Gopalan, A.K., Nair, S.N., Kavillimakkil, A.K., Bandyopadhyay, A., Rawat, A.K., and Ghosh, S. (2012). *Jatropha curcas* (Linn) leaf extract -a possible alternative for population control of *Rhipicephalus (Boophilus) annulatus*. Asian Pacific J of Trop Dis. 2012: 225-229.
32. Santhoshkumar, T., Rahuman, A.A., Bagavan, A., Kirthi, A.V., Marimuthu, S., Jayaseelan, C., Kamaraj, C., Zahir, A.A., Elango, G., Rajakumar, G., and Velayutham, K. (2012). Efficacy of adulticidal and larvicidal properties of botanical extracts against *Haemaphysalis bispinosa*, *Hippobosca maculata*, and *Anopheles subpictus*. Parasitol Res, 111(4): 1833-1840.
33. Schwalbach, L.M.J., Greyling, J.P.C., and David, M. (2003). The efficacy of 10% aqueous Neem (*Azadirachta indica*) seed extract for tick control in Small East African and Toggenburg female goat kids in Tanzania. S African J of Anim Sci, 33(2): 83-88.
34. Şincai, M. (2000). Histologie Veterinară (in Romanian), Ed. Mirton, Timișoara.
35. Shih, M.F., and Cherng, J.Y. (2012). Potential Applications of *Euphorbia hirta* in Pharmacology in: Drug Discovery Research in Pharmacognosy, Omboon Vallisuta (Ed.) ISBN: 978-953-51-0213-7, InTech, <http://www.intechopen.com/books/drug-discovery-research-in-pharmacognosy/potentialapplications-of-euphorbia-hirta-in-pharmacology>
36. Singh, G.B., Kaur, S., Satti, N.K., Atal, C.K., and Maheswari, J.K. (1984). Anti-inflammatory activity of *Euphorbia acaulis* Roxb. J Ethnopharmacol, 10: 225-233.
37. Spiewak, R. (2008). Patch Testing for Contact Allergy and Allergic Contact Dermatitis The Open Allergy Journal, 1: 42-51. <http://benthamscience.com/open/toallj/articles/V001/42TOALLJ.pdf>
38. SVH AEC SOP.26 (2006). Euthanasia of mice and rats. (Sue Pierce).
39. Tabuti, J.R.S/ (2008). *Euphorbia hirta* L. In: Schmelzer, G.H. & Gurib-Fakim, A. (Editors). Prota 11(1): Medicinal plants / Plantes médicinales 1. [CD-Rom]. PROTA, Wageningen, The Netherlands.
40. Walton, S.F., Mc.Kinnon, M., Pizzutto, S., and Dougall, A. (2004). Acaricidal activity of *Melaleuca alternifolia* oil: *in vitro* sensitivity of *Sarcoptes scabiei* Var. *hominis* to terpinen-4-ol. Arch Dermatol, 140: 563-566.
41. Wang, Z.Y., Liu, H.P., Zhang, Y.C., Guo, L.Q., Li, Z.X., and Shi, X.F. (2012). Anticancer potential of *Euphorbia helioscopia* L. extracts against human cancer cells. Anat Rec, 295: 223-233.
42. Webb, E.C., and David, M. (2002). The efficacy of neem seed extract (*Azadirachta indica*) to control tick infestation in Tswana, Simmentaler and Brahman cattle. S African J Anim Sci, 32(1): 1-6.
43. Zahir, A.A., and Rahuman, A.A. (2012). Evaluation of different extracts and synthesised silver nanoparticles from leaves of *Euphorbia prostrata* against *Haemaphysalis bispinosa* and *Hippobosca maculata*. Vet Parasitol, 187(3-4): 511-520.