

NEURO-PROTECTIVE EFFECTS OF CROCIN ON BRAIN AND CEREBELLUM TISSUES IN DIABETIC RATS

Eyup ALTINOZ¹, Zulal ONER², Hulya ELBE³, Nigar VARDI³¹Karabuk University, Health High School, Department of Medical Biochemistry, Karabuk, Turkey.²Inonu University, Medical Faculty, Department of Anatomy, Malatya, Turkey.³Inonu University, Medical Faculty, Department of Histology and Embryology, Malatya, Turkey**Corresponding Author:** Phone Number: +90 370 433 0202, E-mail: eyupaltinoz@karabuk.edu.tr**Abstract**

Background: Increase in free oxygen radicals and the disruption of defense system make the neurons and astrocytes more sensitive against oxidative damage.

Materials and Methods: Rats were divided into three groups containing 10, rats in each group namely: control (C) group, Diabetes Mellitus (DM) group, and Diabetes Mellitus + crocin (DM+crocin) group. Tissue samples were processed by routine histological and biochemical procedures. The sections were stained with Hematoxylin-eosin. Malondialdehyde (MDA), glutathione (GSH), blood glucose, HbA1c levels and xanthine oxidase (XO) activities were assayed.

Results: The histological appearance of the cerebrum and cerebellum were normal in the control group. DM group showed some histopathological changes including congestion, perivascular and perineuronal edema in cerebrum. In DM + crocin group, histopathological changes in cerebrum and cerebellum markedly reduced. MDA level and XO activities increased significantly in DM group ($P < 0.01$), but decreased significantly in DM + crocin group when compared to DM group ($P < 0.01$). Blood glucose concentrations increased significantly ($p < 0.01$) in DM group, but decreased significantly in DM + crocin group when compared with DM group ($p < 0.05$). Blood HbA1c levels were normal in control group. But there were significant differences between control and DM groups ($p < 0.01$). On the other hand, blood HbA1c levels decreased in DM+crocin group when compared with the DM group, but it was not statistically significant ($p > 0.05$).

Conclusion: Due to the fact that crocin has an antioxidant and anti-hyperglycemic effects, it can protect the brain and cerebellum tissue against the complications of oxidative stress.

Key words: Diabetes mellitus, oxidative stress, crocin, brain, cerebellum.

Introduction

Diabetes Mellitus (DM) is a common epidemic endocrine disorder. Hyperglycemia induced systemic complications are the main problem of diabetic patients. Hyperglycemia provides more substrate for anaerobic glycolysis which leads to lactic acidosis (Biessels et al. 1994). It has been stated that the tissue damage resulting from hyperglycemia is due to the oxidative injury arising from the increase in the formation of free oxygen radicals (Ercel et al. 1999). Moreover, increase in the formation of free oxygen radicals leads to the depletion of cellular antioxidants, such as glutathione (GSH). The increase of free oxygen radicals and the disruption of defense system make the neurons and astrocytes more sensitive against oxidative damage (Guyot et al. 2000). Previous studies have shown that hyperglycemia induced oxidative stress is the cause of development of several common acute and chronic neuro-degenerative pathologies (Greene et al. 1999; Low et al. 1997).

Oxidative stress causes the increase of free oxygen radicals and/or decrease in antioxidant defense system. The increase in the formation of free oxygen radicals has cytotoxic effects on the membrane phospholipids and leads to the release of toxic substances such as Malondialdehyde (MDA) (Slatter et al. 2000). In addition, free radicals can diffuse into cells and lead to mitochondrial enzyme damage, DNA fractures, disruption of the cellular functions and development of patho-physiology of various diseases (Kristal et al. 1997). Antioxidant defense systems, non-enzymatic free radical scavengers (for example Vitamin E, vitamin C, Uric acid, bilirubin) and antioxidant scavenging enzymes [catalase (CAT), superoxide dismutase (SOD) and glutathione peroxidase (GSH-Px)] protect the tissues against oxidative damage (Bonfont-Rousselot et al. 2000). The central nervous system contains a higher rate of unsaturated fatty acid and lower rate of antioxidant enzyme and has a high level of oxygen consumption (Somani et al. 1996). Thus, it is potentially sensitive to oxidative damage. Increase in the oxidative stress play an important role in the etiology and pathogenesis of chronic complications in diabetic patients (Baynes et al. 1991). It is assumed that hyperglycemia induced oxidative stress leads to the development of diabetic neuropathy (Greene et al. 1999; Low et al. 1997). Again, it has been indicated that xanthine oxidase (XO) is the potential superoxide source in the streptozotocin (STZ) induced experimental diabetes in rats and this condition may be the reason for diabetic complications (Matsumoto et al. 2003).

Saffron is derived by drying the stigma of the flower of *Crocus sativus* L. in the family Iridaceae and mainly grown in Iran, Morocco, India, Greece, Turkey, Spain and France. Besides being used as additive for the foods mainly, it is beneficial as a traditional drug for medical purpose in many diseases including depression, mental disorders and cancer (Schmidt et al. 2007). Crocin (crocin glycoside), crocetin and safranal are the main active ingredients of saffron (Liakopoulou-Kyriakides et al. 2002). In addition, saffron comprises protein, sugars, vitamins, flavonoids, amino acids, vital minerals and other chemical compounds (Abdullaev 1993). It has been reported that *C. sativus* has hypolipemic, anti-inflammatory, antioxidant and anticarcinogenic effects (Hosseinpour et al. 2010; Abdullaev 2002). Currently, it has been reported that saffron extract, crocin and safranal have remarkable radical scavenging activities (Assimopoulou et al. 2005).

The purpose of the present study was to investigate the neuro-protective effect of crocin on hyperglycemia induced oxidative stress by measuring MDA, Reduced GSH, XO levels and examining brain and cerebellum tissues morphologically..

Materials and Methods

Experimental Animals

In this study, 30 female Wistar albino rats (Experimental Research Unit of Inonu University Faculty of Medicine, Malatya, Turkey), weighing between 170-200 g, were housed in a room with a mean constant temperature of 21°C, moisture at the rate of 55-60% and a light/ dark photo-period of 12:12 (08:00 and 20:00). Animals were fed with standard rat chow and tap water *ad libitum*. The experiments were performed in accordance with the Guide for the Care and Use of Laboratory Animals of Inonu University Animal Ethic Committee.

Experimental Design

At the onset of the study, each rat was weighted and blood samples were taken from tail veins for the measurement of blood glucose levels. The rats were randomly divided into three groups each consisting 10 rats as follows: control (C; non-diabetic rats) group; Diabetes mellitus (DM; STZ-induced untreated diabetic rats) group; Diabetes Mellitus + crocin (DM + crocin; STZ-induced diabetic rats treated with crocin) group. Streptozotocin (STZ; Sigma Chemical Co., St. Louis, MO, USA) dissolved in 0.01 M sodium citrate buffer (pH 4.5) was administered at a single dose of 50 mg/kg body weight via intra-peritoneal (i.p.) injection in both DM and DM + crocin group, but 1 ml sodium citrate buffer was injected via i.p. injection in only C group. Three days after administration of STZ, blood glucose levels of all groups were measured with a glucometer (Accu-Check Active, ROCHE, Germany) in samples obtained from the tail vein by using reagent strips (Accu-Check Active Glucose test strips, ROCHE, Germany). It was observed that blood glucose levels were within normal limits in C group; however, the blood glucose levels were above 270 mg/dl in STZ and STZ + crocin groups and these rats were considered as diabetic. Normal saline was administered in C and DM groups; and crocin (Sigma Chemical Co., St. Louis, MO, USA) dissolved in normal saline was administered in DM+crocin group at a dose of 20 mg/kg/day (Zheng et al. 2007). All the administrations were performed at the same hour and continued for 21 days with a volume of 5 mL/kg body weight/day via gavage. At the end of the study, all animals were anesthetized under the ketamine anesthesia. Trunk blood was collected to determine the blood glucose and HbA1c levels. The brain and cerebellum tissues were removed rapidly and brain tissue was divided into two equal pieces. One of the brain pieces and cerebellum were placed into 10% formaldehyde for routine histo-pathological examination by means of light microscope. The other brain pieces were stored at -80 °C for MDA, GSH and XO activity measurement.

Biochemical Analysis

The brain tissue was homogenized in ice within 1 M Tris-HCl buffer (pH 7.5) (includes Protease inhibitor, phenylmethylsulfonyl fluoride, PMSF, 1mM) with homogenisator (IKA Ultra Turrax T25 basic) at 16.000 rpm and at +4°C for 3 minutes. The homogenates were used in the measurement of MDA, GSH and XO. All the procedures were performed at +4°C. The main principle of the analysis is based on the fact that MDA in the medium reacts when heated with thiobarbituric acid and creates a pink chromogen. The intensity of the pink color is in direct proportion to MDA concentration. MDA levels were assayed spectrophotometrically at 535 and 520 nm in accordance with the method of Ohkawa et al. (Ohkawa et al. 1979). Results were explained as nmol/g wet tissue.

GSH levels were measured with Elman (Elman 1959) method. When GSH reacts with 5,5-dithiobis-2-nitrobenzoic acid, the resulting product provides maximal absorbance at 410 nm. Results were explained as nmol/g wet tissue.

XO activity was studied in accordance with Prajda and Weber (Prajda and Weber 1975) method and absorbance increase in the formation of uric acid from xanthine was recorded at 292 nm (ϵ_M 9.2 x 10³). One unit of activity was defined as 1 µmol of uric acid formed per minute, and results were explained as U/g protein.

Protein levels were measured using the Bradford method (Bradford 1976). The absorbance was recorded at 595 nm using a UV-VIS spectrophotometer. Bovine serum albumin (BSA) was used as protein standard.

Serum glucose concentration and HbA1c were performed an Abbott Architect c 1600 automatic analyzer using commercially available kits.

Histological determination

At the end of the study, the cerebrum and cerebellum tissues were placed in 10% formaldehyde and were prepared for routine paraffin embedding. Paraffin blocks were cut at 5 µm thick, mounted on slides, stained with hematoxylin-eosin (H-E). Cerebrum (congestion, perineuronal and perivascular edema) and cerebellum (Purkinje cell degeneration and loss of Purkinje cell) sections were examined for severity of histopathological changes. For this analysis, tissue injury was semiquantitatively graded as (0) normal, (1) mild, (2) moderate, (3) severe, for each criterion. All sections were examined using a Leica DFC280 light microscope and a Leica Q Win and Image Analysis system (Leica Micros Imaging Solutions Ltd., Cambridge, UK).

Statistical Analysis

Statistical analysis was carried out using the SPSS for Windows version 13.0 (SPSS Inc., Chicago, III., USA) statistical program. Results were expressed as mean ± standart error of the mean (mean±SE). Normality for continued variables in groups were determined by the Shapiro Wilk test. The variables did not show a normal distribution (p <0.05). So, Kruskal-Wallis and Mann-Whitney U tests were used for comparison of variables among the studied groups. P <0.05 was regarded as significant.

Results

MDA, GSH and XO levels are presented in Table 1. It was detected that MDA and XO activities increased significantly in DM group (P<0.01) compared with C group. When DM group was treated with crocin, MDA levels and XO activities decreased significantly in DM+crocin group (P <0.01) compared to DM group.

Table 1: Comparison of the effect of crocin on brain MDA and GSH contents and XO enzyme activities among the experimental groups.

GROUPS	MDA (nmol/g wet tissue)	GSH (nmol/g wet tissue)	XO (U/g Protein)
C	518±32,2	1127±27,1	0,086±0,007
DM	795±45,5 ^a	987±25,1 ^a	0,145±0,015 ^a
DM + crocin	483±29,1 ^b	1075±17,6 ^c	0,070±0,015 ^b

Data are expressed as mean ± SE. ^ap<0.01 vs Control rats; ^bp<0.01 vs DM; ^cp<0.05 vs DM.

Diabetes also caused a significant decrease in the GSH levels in DM group (P <0.01). However, when pre-treatment of the DM animals with crocin, GSH levels increased significantly in DM + crocin group (P <0.01) and reached a level that was close to the levels of C group.

Mean blood glucose and HbA1c levels are presented in Table 2. At the end of the study, blood glucose concentration was found to be at normal levels in C group. However, when DM and DM + crocin groups were compared with C group, it was observed that blood glucose concentrations increased significantly (p<0.01). In addition, when DM + crocin group was compared with DM group, blood glucose concentrations decreased significantly (p<0.05).

Table 2: The blood glucose and Hba1c levels of all groups.

GROUPS	Glucose (mg/dL)	Hba1c (% Units)
C	75±25,5	2,48±0,234
DM	488±15,38 ^a	9,33±0,339 ^a
DM + Crocin	424±31,23 ^b	8,66±0,390

Values are expressed as mean ± SE. ^ap<0.01 vs Control rats; ^bp<0.05, compared to DM rats.

It was observed that blood HbA1c levels were normal in C group. But there were significant differences between C and DM groups (p<0.01). On the other hand, it was found that blood HbA1c levels decreased in DM + crocin group compared with DM group, but it was not statistically significant (p > 0.05).

Table 3. The histopathological damage score of all groups.

Score	C	DM	DM+crocin
Cerebrum damage	0.12 ± 0.12	6.25±0.36 ^a	2.25±0.36 ^b
Cerebellum damage	0.00 ± 0.00	4.87± 0.22 ^a	2.12±0.22 ^b

Data are expressed as mean ± SE. ^ap <0.0001 vs control group, ^bp =0.001 vs DM group.

The histopathological damage scores are presented in Table 3. The histological appearance of the cerebrum and cerebellum were normal in C group (Figs. 1a, b). DM group showed some histopathological changes including congestion, perivascular and perineuronal edema in cerebrum (Figs. 2a, b). In addition, we also detected subarachnoidal hemorrhage and congestion in choroid plexus (Figs. 2c, d). Furthermore, in cerebellum, purkinje cell degeneration, loss of purkinje cell and hemorrhagic areas were observed (Figs. 3a, b). In DM + crocin group, histopathological changes in cerebrum and cerebellum markedly attenuated (Figs. 4a, b). There was a significant difference between DM and DM + crocin group (p =0.001, for both).

Discussion

The present study showed that crocin is protective against increased ROS in oxidative stress arising from STZ induced diabetes and contributes to protection of brain and cerebellum tissues.

In accordance with the previous studies, we showed in the present study that STZ induced diabetes mellitus leads to oxidative stress in brain tissue (Low et al. 1997; Ozbek et al. 2003). Previous studies showed that oxidative stress and the secondary lipid peroxidation were increased in DM (Cerutti and Chadi 2000; Marshak et al. 1992; Moosmann and Behl 2002). Diabetes induced hyperglycemia results in

<http://dx.doi.org/10.4314/ajtcam.v11i6.2>

disruption in glucose homeostasis and this condition is the reason for the oxidative stress and lipid peroxidation. As STZ induced diabetes results in hyperglycemia, it is an example to the endogenous chronic oxidative stress (Low et al. 1997). Due to hyperglycemia, the formation of reactive

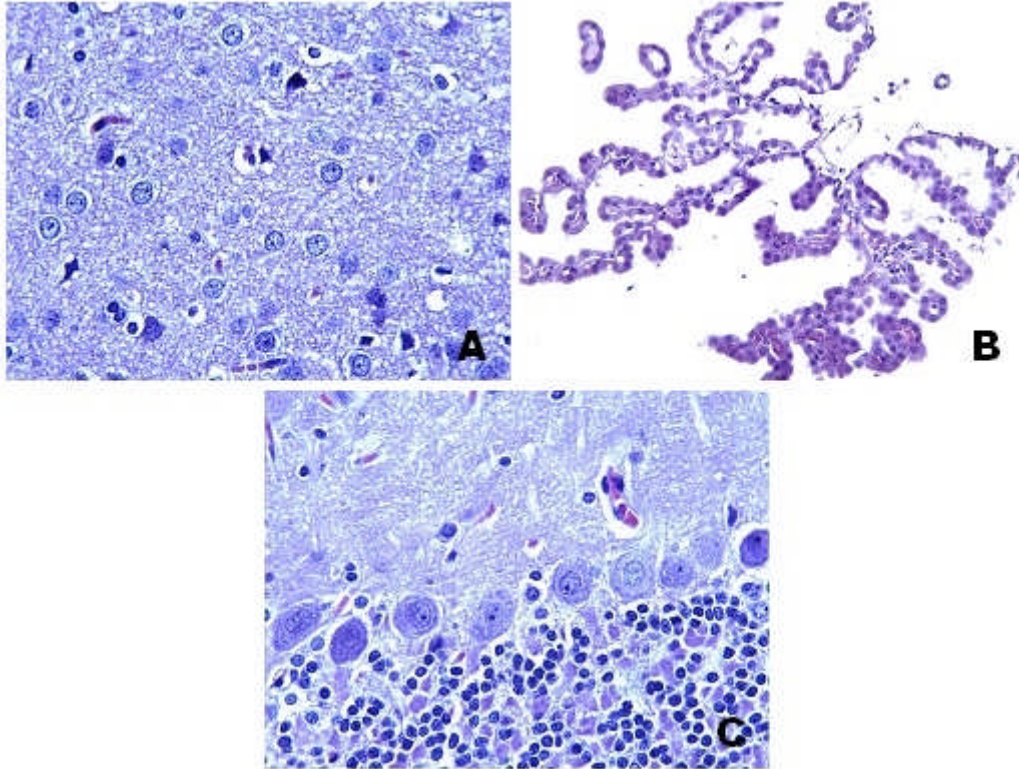


Figure 1. C group. **A.** Histological appearance was normal in cerebrum. H-E; X40. **B.** Choroid plexus, H-E; X20. **C.** Cerebellum tissue was normal. H-E; X40.

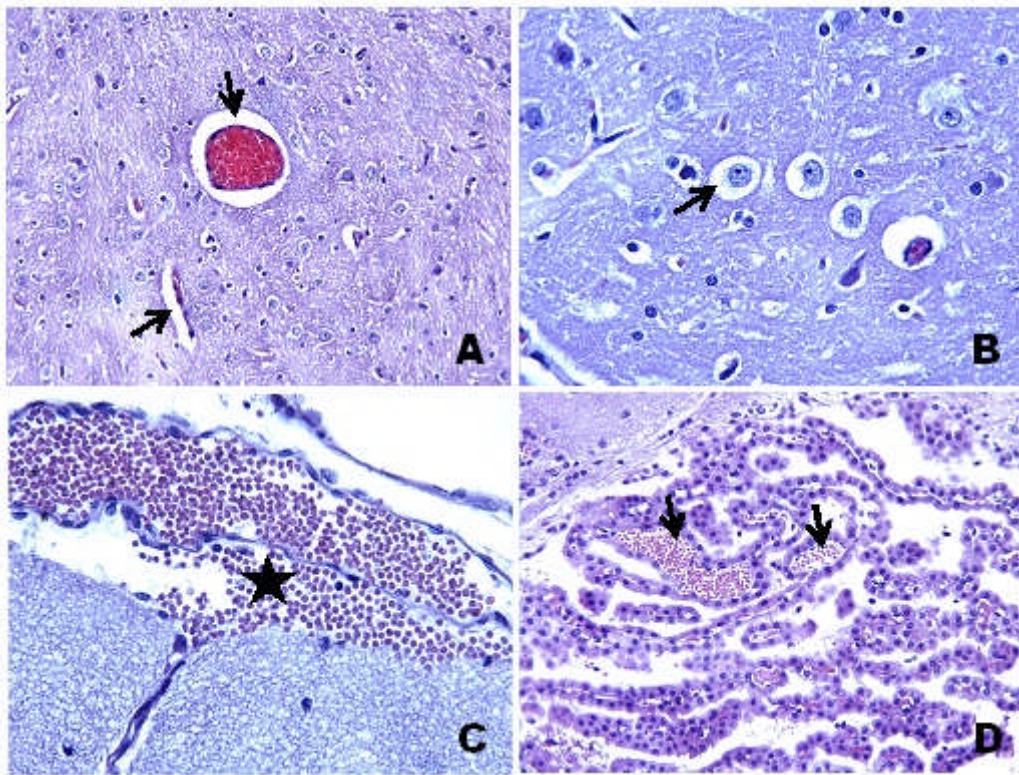


Figure 2. Cerebrum tissues of the DM group. **A.** Congestion and perivascular edema (arrows), H-E; X20. **B.** Perineuronal edema (arrow), H-E; X40. **C.** Subarachnoid hemorrhage (star), H-E; X40. **D.** Congestion in choroid plexus (arrows), H-E; X20.

<http://dx.doi.org/10.4314/ajtcam.v11i6.2>

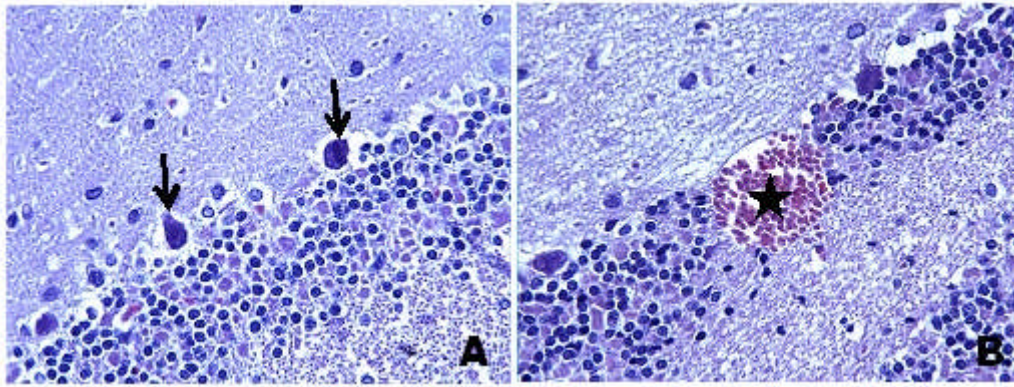


Figure 3. Cerebellum tissues of the DM group. **A.** Degenerated Purkinje cell (arrows) and loss of Purkinje cell, H-E; X40. **B.** Hemorrhagic area in cerebellum (star), H-E; X40.

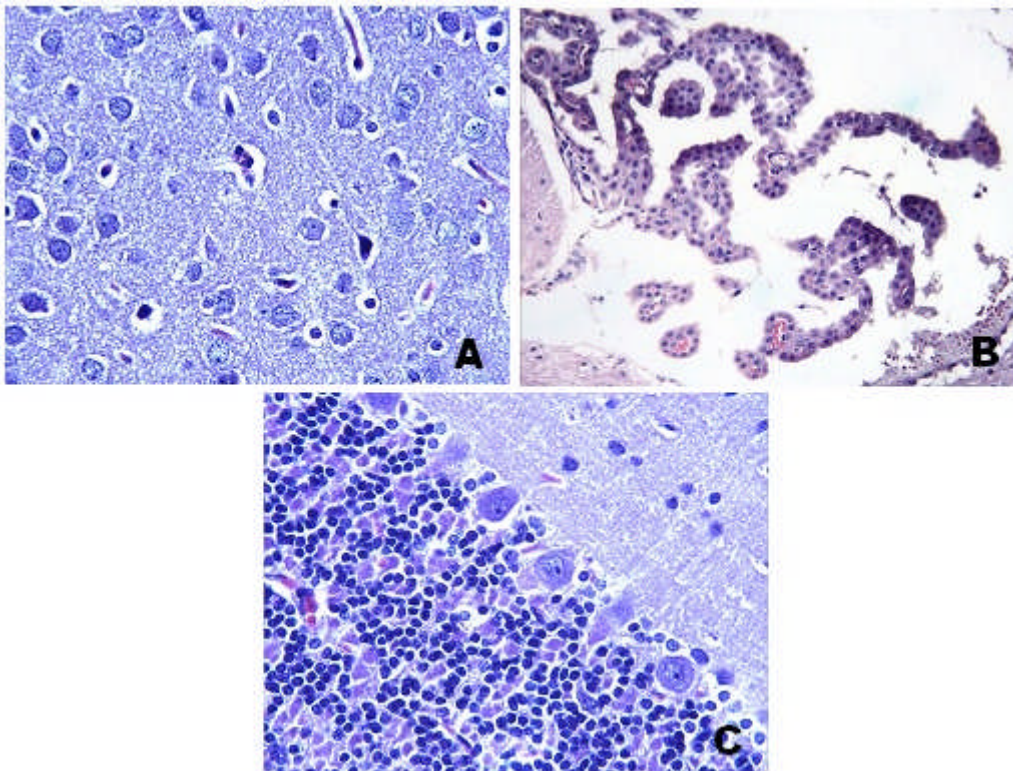


Figure 4. DM+crocin group. **A.** Histopathological findings markedly reduced in cerebrum. H-E; X40. **B.** Choroid plexus, H-E; X20. **C.** Cerebellum tissue was similar to control. H-E; X40.

oxygen species (ROS) increases in diabetes and nitrogen types; as results , proteins are oxidized, DNA is damaged, lipid peroxidation products increase in cell membrane and the rates of neuronal deaths are increased (Luxford et al. 2000; Hawkins and Davies 2001). Oxidative stress plays an important role in the brain tissue damage. Brain needs high level of oxygen and unsaturated lipid content. These two features may make the brain tissue a target for the formation of oxygen radicals and lipid peroxidation. The potential oxidative stress sources including diabetes lead to the auto-oxidation of glucose, decrease in the glutathione concentration of tissue, damaged antioxidant enzyme activities and increase in ROS formation (McLennan et al. 1991). The remarkable depletion of antioxidants such as GSH increases the sensitivity of brain tissue against oxidative changes in diabetes.

The pharmacological treatment with antioxidants may protect the brain tissue against ROS increase during oxidative stress. Due to its antioxidant property, crocin may be used as a pharmacological agent in cases that results in cerebral ischemia (Lee et al. 2005). The modern pharmacological studies have shown that saffron extract and active contents of it have anti-tumor effects, radical scavenger properties, hypolipemic effect and memory-improving effect (He et al. 2005; Sugiura et al. 1994; Zhang et al. 1994). In addition, it has also been reported that saffron extract regulates cerebral MDA, SOD, CAT, GSH-Px activities and glutamate and aspartate metabolism (Saleem et al. 2006). The most common content of saffron, whose antioxidant effects have been studied, is crocin (Abdullaev 1993). It has been indicated in a study that crocin has an antioxidant feature stronger than α -tocopherol, it inhibits the death of neurons induced by oxidative stress and the formation of lipid peroxidation, and restores SOD activity (Ochiai et al. 2004).

The previous studies have indicated that saffron elevates SOD, CAT and GSH-Px activities and inhibits the lipid peroxidation (Premkumar et al. 2003). Recently, it has been reported that safranal, an active content of saffron, treats the cerebral ischemia-reperfusion induced oxidative stress and decreases the increased MDA levels (Hosseinzadeh et al. 2005). In addition, when crocin was administered as 20 and

<http://dx.doi.org/10.4314/ajtcam.v11i6.2>

10 mg/kg in a study on cerebral ischemia-reperfusion damage, it decreased the elevated MDA levels significantly and increased SOD and GSH-Px levels significantly (Zheng et al. 2007).

In the present study, lipid peroxidation arising in STZ induced diabetes has been observed by measuring MDA. Because MDA occurs as a result of damage in the cellular membrane components caused by free radicals. We found that the MDA levels increased as a result of diabetes induced oxidative stress, but MDA and lipid peroxidation decreased significantly after crocin treatment.

The potential harmful effects of ROS are controlled by cellular antioxidant defense systems including enzymatic defense systems such as SOD and CAT, and non-enzymatic defense systems such as reduced glutathione (GSH) and uric acid. GSH is an important non-enzymatic molecule against ROS in cellular defense system. It is oxidized as a result of ROS detoxification and is transformed into glutathione disulfide (GSSG) and this condition decreases GSH levels. Damage in the tissue GSH levels increases the cellular damage caused by oxidative stress. The potential reason of the increase in lipid peroxidation in STZ induced DM group may be the decrease of GSH levels. In accordance with the previous studies (Tachi et al. 2001; Dincer et al. 2002), Baydas et al. (Baydas et al. 2003) have reported that untreated diabetes generally causes lower GSH levels in different areas of the brain. Moreover, we also represented in the present study that GSH levels in the crocin treated diabetes group were significantly higher than the untreated diabetes group. Furthermore, Hosseinzadeh and Sadeghnia have showed in their studies that the levels of total thiol groups decreased in ischemia-reperfusion induced brain damage and increased significantly after safranal treatment; these results also support our study (Premkumar et al. 2003).

Free oxygen radicals are generated from several sources at cellular level. It is known that a vital free oxygen radical source is XO and it may occur from xanthine dehydrogenase (XD) in a reversible manner in pathologic conditions (blockage and oxidation of thiol groups), or in an irreversible manner (by limiting proteolysis) (Hile et al. 1995). In normal tissue, XD catalyzes the transformation reaction of hypoxanthine into xanthine and uric acid and uses NAD^+ as electron acceptor. In fact, this reaction does not normally lead to the formation of free oxygen radicals or the formation of hydrogen peroxide (H_2O_2). However, XO can also catalyze the formation of superoxide (O_2^-) and H_2O_2 in pathological condition and the reaction is assumed to form the mechanism of oxidative stress injury (Hile et al. 1995; Corte and Stirpe 1972). It has been shown that the important source of increased ROS in STZ induced diabetic rats is XO (Parks et al. 1988). Additionally, the formation of free radical and the decrease of oxidative stress may be ensured by administering XO inhibitors such as allopurinol in diabetics (Desco et al. 2002). In our study, XO activity in the brain tissue in DM group has increased significantly when compared to DM + crocin group. However, XO activity decreased significantly after crocin treatment in DM + crocin.

Diabetes mellitus is characterized with hyperglycemia and is a disease related to the chronic disorders of carbohydrate, protein and lipid metabolisms. If diabetes is not treated in time, it causes some complications such as atherosclerosis, nephropathy, retinopathy, and neuropathy (Marjani et al. 2010; Shane-McWhorter 2005). In a study conducted by forming diabetes model, the blood glucose of healthy rats has decreased 28% with the intra-peritoneal injection of ethanolic saffron extract and this decrease has been around 40% in diabetic rats (Mohammed et al. 2011). In addition, saffron extract has been reported to have hypoglycemic effect (Mohajeri et al. 2008). It has been observed in our study that the blood glucose concentration and HbA1c levels of the group in which STZ induced experimental diabetes is formed, have increased significantly when compared to non-diabetic group. When crocin treated group has been compared with the untreated diabetes group, blood glucose concentration and HbA1c levels have decreased. These results have showed that crocin has hypoglycemic effect.

When cerebrum and cerebellum were analyzed histo-pathologically, severe histopathological alterations occurred in the DM group such as congestion, perivascular and perineuronal edema in cerebrum. In addition, we also detected subarachnoidal hemorrhage and congestion in choroid plexus. Furthermore, in cerebellum, Purkinje cell degeneration, loss of Purkinje cell and hemorrhagic areas were observed. In DM+Crocin group, histopathological changes in cerebrum and cerebellum markedly attenuated. There were significant differences between DM and DM+Crocin group. These results are in line with Zheng YQ et al. studies (Zheng et al. 2007), which indicated that crocin protects the brain against excessive oxidative stress and constitutes a potential therapeutic candidate in global cerebral ischemia.

In conclusion, the results have showed that STZ induced hyperglycemia leads to significant oxidative stress in the brain and cerebellum. Due to the fact that crocin has an antioxidant and anti-hyperglycemic effects, it can protect the brain and cerebellum tissue against the complications of oxidative stress. However, more studies is needed relating the neuro-protective efficiency of crocin.

References

1. Abdullaev, F.I. (1993). Biological effects of saffron. *Biofactors* 4: 83–86.
2. Abdullaev, F.I. (2002). Cancer chemopreventive and tumoricidal properties of saffron (*Crocus sativus* L.). *Exp Biol Med* 227: 20-25.
3. Assimpoulou, A.N., Sinakos, Z., Papageorgiou, V.P. (2005). Radical scavenging activity of *Crocus sativus* L. extract and its bioactive constituents. *Phytother Res* 19: 997-1000.
4. Baydas, G., Reiter, R.J., Yasar, A., Tuzcu, M., Akdemir, I., Nedzvetskii, V.S. (2003). Melatonin reduces glial reactivity in the hippocampus, cortex, and cerebellum of streptozotocin-induced diabetic rats. *Free Radic Biol Med* 35(7): 797–80.
5. Baynes, J. (1991). Role of oxidative stress in development of complications in diabetes. *Diabetes* 40: 405–412.
6. Biessels, G.J., Kappelle, A.C., Bravenboer, B., Erkelens, D.W., Gispen, W.H. (1994). Cerebral function in diabetes mellitus. *Diabetologia* 37: 643–650.
7. Bonnefont-Rousselot, D., Bastard, J.P., Jaudon, M.C., Delatre, J. (2000). Consequences of the diabetic status on the oxidant/antioxidant balance. *Diabetes Metab* 26: 163–176.
8. Bradford, M.M. (1976). A rapid and sensitive method for the quantitation of microgram quantities of protein utilizing the principle of protein-dye binding. *Analytical Biochemistry* 72: 248-54.
9. Cerutti, S.M. and Chadi, G. (2000). S100 immunoreactivity is increased in reactive astrocytes of the visual pathways following a mechanical lesion of the rat occipital cortex. *Cell Biol Int* 24: 35–49.
10. Corte, E.D., and Stirpe, F. (1972). The regulation of rat liver xanthine oxidase. Involvement of thiol groups in the conversion of the enzyme activity from dehydrogenase (type D) into oxidase (type O) and purification of the enzyme. *Biochem J* 126 (3): 739–745.
11. Desco, M.C., Asensi, M., Marquez, R., Valls, J.M., Vento, M., Pallardo, F.V., Sastre, J., Vina, J. (2002). Xanthine oxidase is involved in free radical production in type 1 diabetes: Protection by allopurinol. *Diabetes*; 51: 1118–1124.
12. Dincer, Y., Akcay, T., Aladmir, Z., Ilkova, H. (2002). Effect of oxidative stress on glutathione pathway in red blood cells from patients with insulin-dependent diabetes mellitus. *Metabolism* 51: 1360–1362.
13. Elman, G.L. (1959). Tissue sulphhydryl groups. *Arch Biochem Biophys* 82: 70–77.
14. Ercel, E., Baydas, G., Akyol, A., Eksioğlu, E., Canpolat, L. (1999). The effect of vitamin E on the sciatic nerve lipid peroxidation in streptozotocin induced diabetes mellitus. *Biomed Res* 10: 95–101.

<http://dx.doi.org/10.4314/ajtcam.v11i6.2>

15. Greene, D.A., Stevens, M.J., Obrosova, I., Feldman, E.L. (1999). Glucose-induced oxidative stress and programmed cell death in diabetic neuropathy. *Eur J Pharmacol* 375: 217–223.
16. Guyot, L.L., Diaz, F.G., O'Regan, M.H., Song, D., Phillis, J.W. (2000). The effect of topical insulin on the release of excitotoxic and other amino acids from the rat cerebral cortex during streptozotocin-induced hyperglycemic ischemia. *Brain Res* 872: 29–36.
17. Hawkins, C.L., and Davies, M.J. (2001). Generation and propagation of radical reactions on proteins. *Biochem Biophys Acta* 1504: 196–219.
18. He, S.Y., Qian, Z.Y., Tang, F.T., Wen, N., Xu, G.L., Sheng, L. (2005). Effect of crocin on experimental *Crocus sativus* atherosclerosis in quails and its mechanisms. *Life Sci* 77: 907–921.
19. Hile, R., and Nishino, T. (1995). Flavoprotein structure and mechanism. 4. Xanthine oxidase and xanthine dehydrogenase. *FASEB J* 9(11): 995–1003.
20. Hosseinpour, C.S., Fadzilah, A.A.M., Mohamad, R.S., Taghizadeh, E., Salehnezhad, S. (2010). Impact of saffron as an anti-cancer and anti-tumor herb. *Afr J Pharm Pharmacol* 4(11): 834–840.
21. Hosseinzadeh, H., Sadeghnia, H.R. (2005). Safranal, a constituent of (saffron), attenuated cerebral ischemia induced oxidative damage in rat hippocampus. *J Pharm Pharm Sci* 8: 394–399.
22. Kristal, B.S., Koopmans, S.J., Jackson, C.T. Ikeno, Y., Park, B.S., Yu, B.P. (1997). Oxidant-mediated repression of the mitochondrial transcription in diabetic rats. *Free Radic Biol Med* 22: 813–822.
23. Lee, I.A., Lee, J.H., Baek, N.I. Kim, D.H. (2005). Antihyperlipidemic effect of crocin isolated from the fructus of *Gardenia jasminoides* and its metabolite crocetin. *Biol Pharm Bull* 28: 2106–2110.
24. Liakopoulou-Kyriakides, M., Kyriakidis, D.A. (2002). *Crocus sativus* biological active constituent. *Studies Nat Prod Chem* 26: 293 – 312.
25. Low, P.W., Nickander, K.K., Tritschler, H.J. (1997). The role of oxidative stress and antioxidant treatment in experimental diabetic neuropathy. *Diabetes* 46: 38–42.
26. Luxford, C., Dean, R.T., Davies, M.J. (2000). Radicals derived from histone hydro peroxides damage nucleobases in RNA and DNA. *Chem Res Toxicol* 13: 665–672.
27. Marjani A (2010) Lipid peroxidation alteration in type 2 diabetic patients. *Pak J Biol Sci* 13: 723-730.
28. Marshak, D.R., Pesce, S.A., Stanley, L.C., Griffin, W.S. (1992). Increased S100 neurotrophic activity in Alzheimer disease temporal lobe. *Neurobiol Aging* 13: 1–7.
29. Matsumoto, S., Koshiishi, I., Inoguchi, T., Nawata, H., Utsumi, H. (2003). Confirmation of superoxide generation via xanthine oxidase in streptozotocin-induced diabetic mice. *Free Radic Res* 37(7): 767–772.
30. McLennan, S.V., Heffernan, S., Wright, L., Rae, C., Fisher, E., Yue, D.K., Turtle, J.R. (1991). Changes in hepatic glutathione metabolism in diabetes. *Diabetes* 40: 344–348.
31. Mohajeri, D., Amouoghli, Tabrizi B., Mousavi, G.H., Mesgari, M. (2008). Anti-diabetic activity of *Crocus sativus* L. (saffron) stigma ethanolic extract in alloxan-induced diabetic rats. *Res J Biol Sci* 3(9): 1102-1108.
32. Mohammed, R., Daryoush, M., Ali, R., Yousef, D., Mehrdad, N. (2011). Attenuation of oxidative stress of hepatic tissue by ethanolic extract of saffron (dried stigmas of *Crocus sativus* L.) in streptozotocin (STZ)-induced diabetic rats. *African Journal of Pharmacy and Pharmacology*. 5(19): 2166-2173.
33. Moosmann, B., and Behl, C. (2002). Antioxidants as treatment for neurodegenerative disorders. *Expert Opin Investig Drugs* 11: 1407–1435.
34. Ochiai, T., Ohno, S., Soeda, S., Tanaka, H., Shoyama, Y., Shimeno, H. (2004). Crocin prevents the death of rat pheochromyctoma (PC-12) cells by its antioxidant effects stronger than those of alpha-tocopherol. *Neurosci Lett* 362: 61–64.
35. Ohkawa, H., Ohishi, N., Yagi, K. (1979). Assay of lipid peroxides in animal tissue by thiobarbituric acid reaction. *Anal Biochem* 95: 351-358.
36. Ozbek, E., Turkoz, Y., Gokdeniz, R., Davarci, M., and Ozugurlu, F. (2000). Increased nitric oxide production in the spermatic vein of patients with varicocele. *Eur Urol* 37(2): 172–175.
37. Parks, D.A., Williams, T.K., Beckman, J.S. (1988). Conversion of xanthine dehydrogenase to oxidase in ischemic rat intestine: A reevaluation. *American Journal of Physiology* 254: 768–774.
38. Prajda, N., and Weber, G. (1975). Malignant transformation-linked imbalance: decreased xanthine oxidase activity in hepatomas. *FEBS Lett*. 59(2): 245–249.
39. Premkumar, K., Abraham, S.K., Santhiya, S.T., Ramesh, A. (2003) Protective effects of saffron (*Crocus sativus* Linn.) on genotoxins-induced oxidative stress in Swiss albino mice. *Phytother Res* 17: 614–617.
40. Saleem, S., Ahmad, M., Ahmad, A.S., Yousef, S., Ansari, M.A., Khan, M.B., Ishrat, T., Islam, F. (2006). Effect of saffron (*Crocus sativus*) on neurobehavioral and neurochemical changes in cerebral ischemia in rats. *J Med Food* 9: 246–253.
41. Schmidt, M., Betti, G., Hensel, A. (2007). Saffron in phytotherapy: pharmacology and clinical uses, *Wien Med Wochenschr* 157: 315-9.
42. Shane-McWhorter, L. (2005). Botanical dietary supplements and the treatment of diabetes: What is the evidence? *Cur Dia Rep* 5: 391 – 8.
43. Slatter, D.A., Bolton, C.H., Bailey, A.J. (2000). The importance of lipid-derived malondialdehyde in diabetes mellitus. *Diabetologia* 43: 550–557.
44. Somani, S.M., Husain, K., Diaz-Phillips, L., Lanzotti, D.J., Kareti, K.R., Trammell, G.L. (1996). Interaction of exercise and ethanol on antioxidant enzymes in brain regions. *Alcohol*. 13(6): 603–610.
45. Sugiura, M., Shoyama, Y., Saito, H., Abe, K. (1994). Crocin (crocetin di-gentiobiose ester) prevents the inhibitory effect of ethanol on long-term potentiation in the dentate gyrus *in vivo*. *J Pharmacol Exp Ther* 271: 703–707.
46. Tachi, Y., Okuda, Y., Bannai, C., Bannai, S., Shinohara, M., Shimpuku, H., Yamashita, K., Ohura, K. (2001). Hyperglycemia in diabetic rats reduces the glutathione content in the aortic tissue. *Life Sci* 69: 1039–1047.
47. Zhang, Y., Shoyama, Y., Sugiura, M., Saito, H. (1994). Effects of *Crocus sativus* L. on the ethanol-induced impairment of passive avoidance performances in mice. *Biol Pharm Bull* 17: 217–221.
48. Zheng, Y.Q., Liu, J.X., Wang, J.N., Xu, L. (2007). Effects of crocin on reperfusion-induced oxidative/nitrative injury to cerebral microvessels after global cerebral ischemia. *Brain Research* 1138: 86-94.