

Galip Erdem¹, Vural Kesik², Tevfik Honca³, Ayhan Özcan⁴, Sami Uğuz⁵, Emin Özgür Akgül³,
Ömer Aykutlug⁶, Bilal Fırat Alp⁵, Nadir Korkmazer⁷, Mehmet Saldır⁷, Ziya Bayrak⁸

Department of Pediatrics¹, Ankara Military Hospital, Dışkapı, Ankara, Turkey, Departments of Pediatric Oncology², Biochemistry³, Pathology⁴, Urology⁵, Physiology⁶, Pediatrics⁷, and Pharmaceutical Sciences⁸, Gulhane Military Medical Faculty, Etlik, 06018, Ankara, Turkey

Corresponding author E-mail: suguz@gata.edu.tr

Abstract

Background: Nephrolithiasis is a severe health problem causing morbidity. Chemolysis, extracorporeal shock wave lithotripsy (SWL), percutaneous nephrolithotomy (PNL), retrograde ureterorenoscopy (URS), and open and laparoscopic surgery are used for treatment with various success rates. Medical treatments with fewer complications were investigated thoroughly.

Materials and Methods: In this study, we evaluated the effects of *Persea americana* (avocado) leaves and *Viburnum opulus* (guelder rose) fruits on nephrolithiasis in an animal model and used 42 rats. The groups received both low and high doses of *Persea americana* leaves and *Viburnum opulus* fruit ethanol extracts orally for 28 days. These two plants have been used for years in Turkey for their nephrolithiatic effect.

Results: Avocado and guelder rose increased the urine volume and urine citrate levels, decreased urine cystine and oxalate levels, and lowered the crystal deposits in kidney tissue. Avocado and guelder rose also prevented oxidant damage and crystal formation in kidney tissue samples.

Conclusion: The two plants that have been used for years for nephrolithiasis treatment in Turkey can safely be used for kidney stones.

Key words: kidney stones; nephrolithiasis; *Persea americana*; *Viburnum opulus*; treatment

Introduction

The prevalence of nephrolithiasis was reported as 8.8% with a significant increase in the worldwide prevalence and incidence especially in the last 25 years (Curhan, 2007; Pearle et al., 2014a). Nephrolithiasis is a severe health problem with an incidence of 3/1000/yr for men and 2.5/1000/yr for women (Curhan, 2007). The risk of nephrolithiasis is 5-9% in Europe, and the risk increases by going west, e.g., Canada and United States have reached 12-15% (Aggarwal et al., 2013). Chemolysis, extracorporeal shock wave lithotripsy (SWL), percutaneous nephrolithotomy (PNL), retrograde ureterorenoscopy (URS), and open and laparoscopic surgery are used for nephrolithiasis treatment with various success rates depending on size, location, and composition of the stones (Türk et al., 2014).

On the other hand, diet therapies and pharmacologic therapies are used with or without these previous treatments (Pearle et al., 2014b). The diet therapy includes drinking enough water to facilitate at least daily 2L micturition, reducing the intake of protein and salt, and avoiding foods with high oxalate content (Nouvenne, 2008). Thiazide diuretics, potassium citrate, allopurinol, and tiopronin drugs are used as pharmacological therapies to decrease the amount of calcium, uric acid, and oxalate, and to increase the amount of citrate, urine pH, phosphate, and pyrophosphate in urine to reduce stone formation (Xu et al., 2013; Marangella et al., 2008).

Herbal treatments were found to be effective on nephrolithiasis in many studies (Patel et al., 2012a; Nizami et al., 2012). The researchers evaluated the efficacy of herbal medication that has been used in their countries for years for the treatment of nephrolithiasis.

We evaluated two of the herbs that are used in our country for nephrolithiasis treatment: *Persea americana* leaves and *Viburnum opulus* fruits. No scientific studies evaluating their antinephrolithiatic effect were found in the literature. Thus, we evaluated the antinephrolithiatic effect of an ethanol extract of leaves of *Persea americana* and fruits of *Viburnum opulus* on a rat nephrolithiasis model.

Material and Methods

Collection and Identification of Plant Materials

Persea americana leaves (avocado: AVCD) were collected from Rize, Turkey, and *Viburnum opulus* fruits (guelder rose: GLBR) were collected from Kayseri, Turkey between May 2014 and June 2014. The leaves and the fruits were dried under conditions without exposure to direct sunlight.

Preparation of Ethanol Extracts

Persea americana leaves (AVCD) and *Viburnum opulus* fruits (GLBR) were milled and extracted by the same procedure. AVCD and GLBR were extracted by 500 g with 5000 mL of solvent for 8 hours. Ethanol – water (90:10) mixture was used as a solvent, which was circulated continuously. Extraction temperature was adjusted to 40°C. The extracts were filtered. The solvent parts of the solutions were evaporated under reduced pressure in a rotary evaporator separately. Then the residues were dried in an oven at 60°C for 12 hours. Pure extracts were obtained. Solutions were prepared with pure extracts in PEG 200 (50% PEG200 and 50% water solution). Finally, concentrations of solutions were adjusted to 10 mg/mL.

Animals and Experimental Model

The study was conducted using 42 male rats (Sprague-Dawley) weighing between 250 and 300 grams aged 10 to 12 weeks old. The rats were housed in stainless steel cages at 21-22°C and 45-50% humidity under artificial lighting with a 12-hour light/dark cycle. All of the groups were fed with standard rodent chow containing 24% protein *ad libitum*. The rats were observed daily throughout the study. All animal procedures were approved by the Institutional Committee on the Care and Use of Animals of our institution. The study was also reviewed and approved by the Ethical Committee on Animal Research.

An ethylene glycol model was used to induce urolithiasis for 28 days in all groups (Marangella et al., 2008). Forty-two animals were randomly divided into six groups: guelder rose low dose (GLBR_LD) (n=8), guelder rose high dose (GLBR_HD) (n=8), avocado low dose (AVCD_LD) (n=8), avocado high dose (AVCD_HD) (n=8), vehicle group (n=5), and a sham group (n=5). All low-dose groups received 0.5 ml, and high-dose groups received 1 ml of the extract orally for five days a week during a one-month period. The sham group received 1 ml of 0.9% saline, and the vehicle group received 1 ml of PEG200 (50% PEG200 and 50% water solution) orally for five days a week for four weeks. All groups received calculi inducing treatment for 28 days, which contained 0.75% v/v ethylene glycol in drinking water *ad libitum*.

Urine, Blood Collection, and Biochemical Analysis

Animals were kept in metabolic cages, and 24-hour urine samples were collected on the 28th day of the experiment. The volume, pH, and crystalluria were determined. Urine was collected into plastic tubes and stored at -20°C. Urine uric acid, urea, creatinine, calcium, magnesium, sodium, potassium, and chloride levels were determined with an Olympus AU2700 autoanalyzer using its own kits (Beckman Coulter GmbH, Krefeld, Germany). Urine citrate and oxalate levels were analyzed using HPLC kits (Eureka Lab Division Chiaravalle, Ancona, Italy). Urine cystine levels were analyzed with an Amino Acid Analyzer ARACUS (MembraPure GmbH, Berlin, Germany). The urine samples were evaluated under a light microscope for the amount of crystal formation and nucleation.

After the experimental period, blood was collected from the aorta under gas anesthesia, and the animals were sacrificed. Serum was separated by centrifugation at 4000g for 10 minutes and analyzed with an Olympus AU2700 analyzer (Olympus Co.Ltd. Tokyo, Japan). The urea, creatinine, calcium, phosphorus, and magnesium levels were tested using commercially available diagnostic kits.

Kidney Histopathology and Homogenate Analysis

The left kidney was removed for histopathological analyses and fixed in 10% buffered formaldehyde and blocked using paraffin. After the routine pathological procedures, 5- μ m thickness slides were prepared. The slides were stained with hematoxylin and eosin (H&E), and then were examined under light microscopy using a specialized pathologist blinded to treatments. The parameters including tubular, glomerular, interstitial, and vascular changes that were used for scoring are detailed in Table 2. The scoring for casts was done by the method described by Patel, Patel, Vyas, Shah, and Gandhi (2012) (Patel et al., 2012b). In addition, the hematoxylin and eosin sections were prepared, and the representative figures are shown in Figure 1. The crystal depositions were counted and scored by a light microscope using a polarized filter (Figure 2).

The right kidney was removed for antioxidant enzyme analysis. Frozen tissues were homogenized in phosphate buffer (pH 7.4) on an ice cube, by a homogenizer (Heidolph Silent Crusher M, Heidolph Instruments, Schwabach, Germany). The supernatant was stored at -80°C. μ Quant (Biotek Instruments, Winooski, VT, USA) and used for spectrophotometric measurements. The kidney tissue homogenate was used for malondialdehyde (MDA) (Okhawa et al., 1979), glutathione peroxidase (GSH) (Paglia et al., 1967), and superoxide dismutase assays (Sun et al., 1988). The MDA levels are expressed as mmol/gprotein. GSH-Px activity is expressed as U/gprotein. The calculated SOD activity is expressed as U/gprotein.

Statistical Analysis

Statistical analyses were conducted using SPSS statistical software (SPSS for Windows, Version 10.0; SPSS Inc., Chicago, IL). The Kruskal-Wallis test was used for variance analyses between groups. Subgroup analyses were performed using the Bonferroni adjusted Mann-Whitney *U* test. $P < 0.05$ was considered to be significant in homogeneous groups.

Results

The urine outputs of the AVCD and GLBR groups were statistically increased as compared with the sham and vehicle groups ($p < 0.05$). However, there was no difference among low and high doses ($p > 0.05$) (Figure 4). The urea and creatinine levels were normal both in serum and urine.

The vehicle (PEG) group increased urine cystine and oxalate levels, but decreased citrate levels. Although urine citrate levels were increased in AVCD and GLBR, it was not statistically significant ($p > 0.05$) (Figure 4). AVCD and GLBR decreased the urine cystine and oxalate levels, the statistical significance of which is given in Table 1. The vehicle group increased urine calcium, uric acid, and phosphate levels. GLBR and AVCD decreased the urine calcium levels in both low and high doses, but they were not statistically significant ($p > 0.05$). GLBR_LD increased the urine calcium levels as compared with the vehicle group. GLBR_LD increased the urine magnesium levels ($p < 0.05$) (Table 1). The MDA levels in GLBR_HD were significantly decreased as compared with the sham and vehicle groups ($p < 0.05$). Superoxide dismutase levels in AVCD_HD were significantly high as compared with the vehicle group ($p < 0.05$). The GSH-Px levels in AVCD_LD, AVCD_HD, and GLBR_HD were significantly high as compared with the vehicle group ($p < 0.05$). The GSH-Px level in AVCD_HD was significantly high as compared with the sham group ($p < 0.05$) (Figure 5). The kidney weight in the vehicle group was statistically higher than all groups ($p < 0.05$). AVCD and GLBR decreased the kidney weight in the vehicle as compared with the vehicle group ($p < 0.05$). The kidney weight in low-dose groups was statistically decreased as compared to high-dose groups ($p < 0.05$). The kidney weights of all the low- and high-dose study groups were higher than the sham group, except GLBR_LD ($p < 0.05$). (Figure 5). The hematoxylin and eosin section examinations revealed focal mild vacuolar changes in the tubular epithelial cells in the sham group and prominent vacuolar changes and flattening in the tubular epithelial cells and hyaline casts in some samples in the vehicle group. In AVCD-HD and GLBR-HD, tubular epithelial cell changes were similar to the vehicle group, but all changes were moderate. In AVCD-LD and GLBR-LD, tubular epithelial cell changes were similar to AVCD-HD, but all changes were milder than those of the HD groups (Figure 1, H&E, x200 for all panels). There were no crystal depositions in tubules of the sham group. However, there were prominent crystals in the tubules of the vehicle group. In AVCD_HD and GLBR_HD, crystal depositions in the tubules were lower than the vehicle group, but higher than the LD groups (Figure 2, H&E with polarized, x200 for all panels). The pathologic scores of the AVCD and GLBR groups both in LD and HD were significantly lower than the vehicle group ($p < 0.05$). The pathologic scores of the AVCD_LD and GLBR_LD groups were significantly lower than the AVCD_HD and GLBR_HD groups ($p < 0.05$) (Table 2).

Discussion

Nephrolithiasis is a major health problem causing severe morbidity, and surgical treatments have potentially serious complications. Thus, new treatments with fewer potential complications were evaluated in-depth. We evaluated the antinephrolithiatic effect of *Persea americana* and *Viburnum opulus*. We clearly showed that avocado and guelder rose increased the urine volume and urine citrate levels, decreased urine cystine and oxalate levels, and lowered the crystal deposits in kidney tissue.

Dietary, pharmacological, and surgical interventions are commonly used treatments for nephrolithiasis. However, there are side effects of these treatments that may cause morbidity and increased risk of hypertension, stroke, and gout in the withdrawals; multicomponent diet, gastrointestinal upset, erectile dysfunction, fatigue, muscle symptoms, anemia, headache, tremor and deep venous thrombosis in the pharmacological interventions; and urosepsis, fever, bleeding, urinary leakage, renal injury, and ureteral perforation in the surgical interventions (Türk et al., 2014; Qaseem, 2014). Thus, medical treatments with fewer side effects have been evaluated for years.

The majority of kidney stones are calcium oxalate with a lesser amount of magnesium phosphate and, in very small amounts, urate and cystine (Aggarwal et al., 2013). The very first phase of kidney stone formation is the super-saturation of the urine with elements such as calcium, oxalate, cystine, and urate. With the addition of oxidative stress and uroepithelial cell injury, the process gains speed, and the crystal formation and aggregation results in stone formation. Citrate inversely inhibits CaOx crystals to bind the uroepithelial cell membrane (Lieske et al., 1995).

We evaluated urine calcium, magnesium, phosphate, oxalate, cystine, and citrate. AVCD and GLBR lowered urinary calcium and phosphate excretion in our study. In addition, AVCD and GLBR increased the urine volume and urine citrate levels, decreased urine cystine and oxalate levels, and lowered the crystal deposits in kidney tissue.

We suggest that AVCD and GLBR were efficient in preventing kidney stone formation by preventing super-saturation of the initiator elements such as calcium, magnesium, phosphate, oxalate, cystine, and citrate. High doses of AVCD and GLBR lowered MDA levels and increased SOD levels. Both AVCD and GLBR increased GPx levels. These findings suggest that AVCD and GLBR also prevented stone formation via inhibiting uroepithelial damage by oxidant injury. One of the major steps in kidney stone formation is crystal formation and aggregation. Although the initiating factor is not clearly known, this process cannot be easily stopped before stone formation. Once the crystal forms, its nuclei in supersaturated urine, proteins, casts, and epithelial cells promote the formation. The process finishes with a well-shaped crystal (Aggarwal et al., 2013). Therefore, the shape of the crystal can give us information about the stone formation process. We found that the groups receiving AVCD and GLBR had abnormal and small crystals. However, the crystals in the vehicle group were well defined (Figure 3). Thus, we suggest that AVCD and GLBR also inhibited stone formation via preventing crystal formation. Herbal treatments have been used for years as a folk remedy for the treatment of nephrolithiasis. *Herniaria hirsuta*, *Phyllanthus niruri*, *Dolichos biflorus*, *Quercus salicina* Blume/*Quercus stenophylla* Makino, *Punica granatum*, *Vaccinium macrocarpon*, and *Andrographis paniculata* were reported as herbs that decreased renal stone formation in earlier in vitro studies, in vivo studies, and clinical trials (Butterweck et al., 2009). In most of these studies, the effect of the herbal treatment was reported via increased urinary

<http://dx.doi.org/10.4314/ajtcam.v13i2.14>

volume with diuretic effect; a decrease of excretion of urinary calcium and oxalate; and an inhibition of calcium oxalate crystallization or anti-oxidative action (Butterweck et al., 2009). In Turkey, *Persea americana* leaves and *Viburnum opulus* fruits are two of the herbs commonly used for the treatment of nephrolithiasis. However, there have been no previous scientific studies proving this effect. We clearly showed that *Persea americana* leaves and *Viburnum opulus* fruits in both low and high doses inhibited renal stone formation by increasing urine citrate and decreasing urine cystine and oxalate excretion, thereby inhibiting calculi and stone formation. Urine output was increased nearly two-fold in the study groups as compared with the sham group. Thus, one of the major antinephrolithiatic effects of these herbs was due to polyuria. The weak part of the study was primarily dependent on the animal model. The model was not able to show aggressive stone formation via preventing urinary flow, thereby causing stone formation in pooled urine and in the parenchyma of the kidney. Because the model allows free urinary flow, the urea and creatinine were also normal. In histopathology, we could not see much crystal formation in renal tissue as described earlier in detail. However, the tubular and interstitial changes were much clearer. The pathological scores of the AVCD and GLBR groups were lower than the vehicle, and LD groups were lower than HD groups. This finding demonstrates that AVCD and GLBR do well in preventing stone formation, but dose increment has no additional effect. The total pathologic score showed that these herbs clearly decreased stone formation via preventing tubular and interstitial damage. In conclusion, avocado and guelder rose have antinephrolithiatic effect by increasing the urine volume, increasing urine citrate, and decreasing cystine and oxalate levels. The additional possible mechanism may be via preventing oxidant damage and crystal formation. These beneficial effects still need to be confirmed in large human studies using various doses.

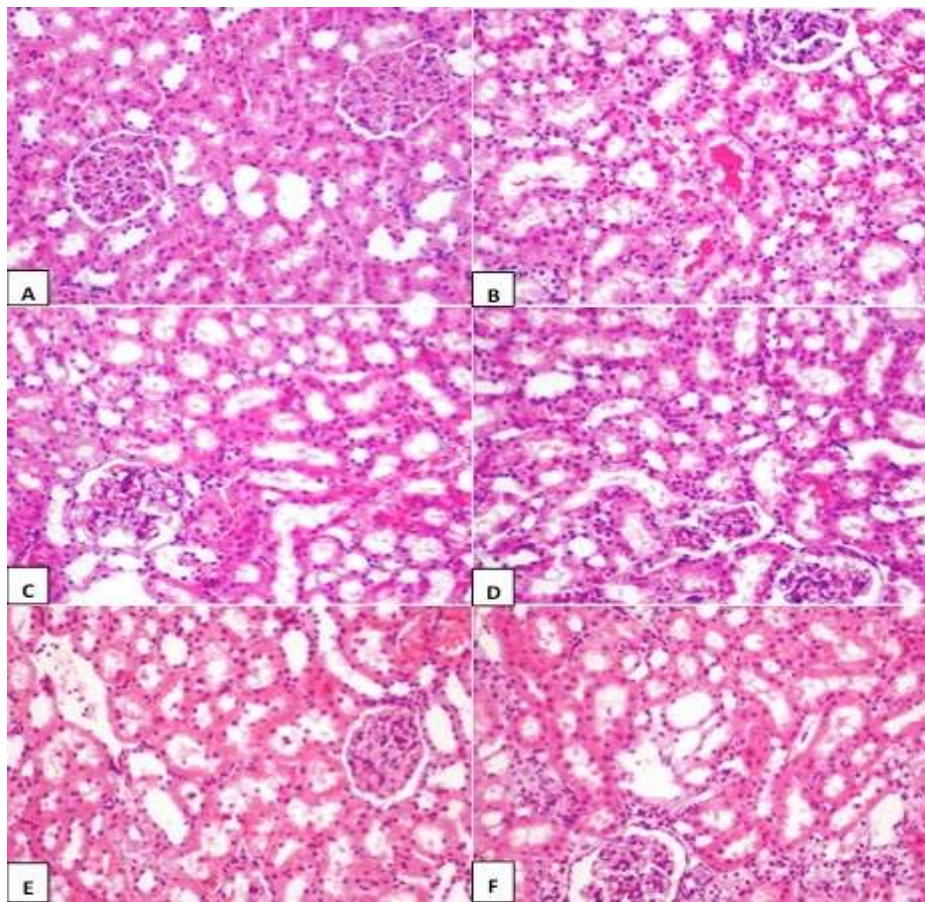


Figure 1: [A] Sham group; focal mild vacuolar changes can be seen in the tubular epithelial cells. [B] Vehicle and sham groups; prominent vacuolar changes and flattening were seen in the tubular epithelial cells. In some, hyaline casts were detected. [C] AVCD_HD; tubular epithelial cell changes were similar to the vehicle and sham groups, but all changes were moderate. [D] AVCD_LD; tubular epithelial cell changes were similar to AVCD_HD, but all changes were milder than those of AVCD_HD. [E] C: GLBR_HD group; tubular epithelial cell changes were similar to AVCD_HD, but all changes were milder than the vehicle and sham groups. [F] GLBR_LD; tubular epithelial cell changes were similar to GLBR_HD, but all changes were milder than those of GLBR_HD like AVCD_LD (H&E, x200 for all panels).

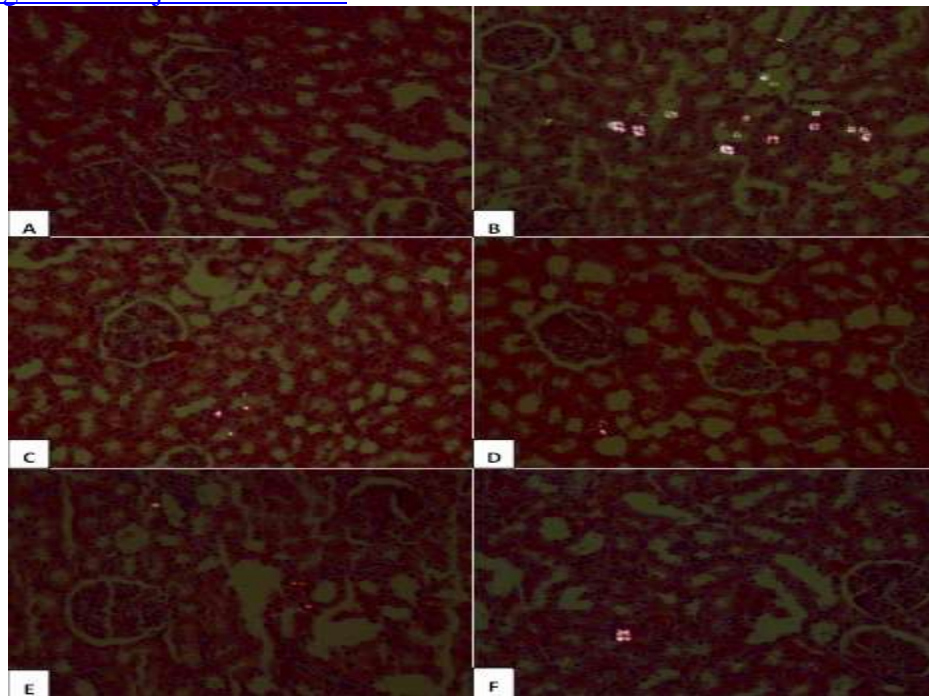


Figure 2: The appearance of crystal depositions: [A] Sham group; no crystal seen in the tubules. [B] Vehicle and sham groups; prominent crystals in the tubules. [C] AVCD_HD; crystal depositions in the tubules were lower than vehicle and sham group, but higher than AVCD_LD. [D] AVCD_LD; crystal depositions in the tubules not much higher than those of AVCD_HD. [E] C: GLBR_HD; crystal depositions in the tubules were similar to AVCD_HD, but lower than vehicle and sham groups. [F] GLBR_LD; crystal depositions in the tubules not much higher than those of GLBR_HD like AVCD_LD (H&E with polarized, x200 for all panels).

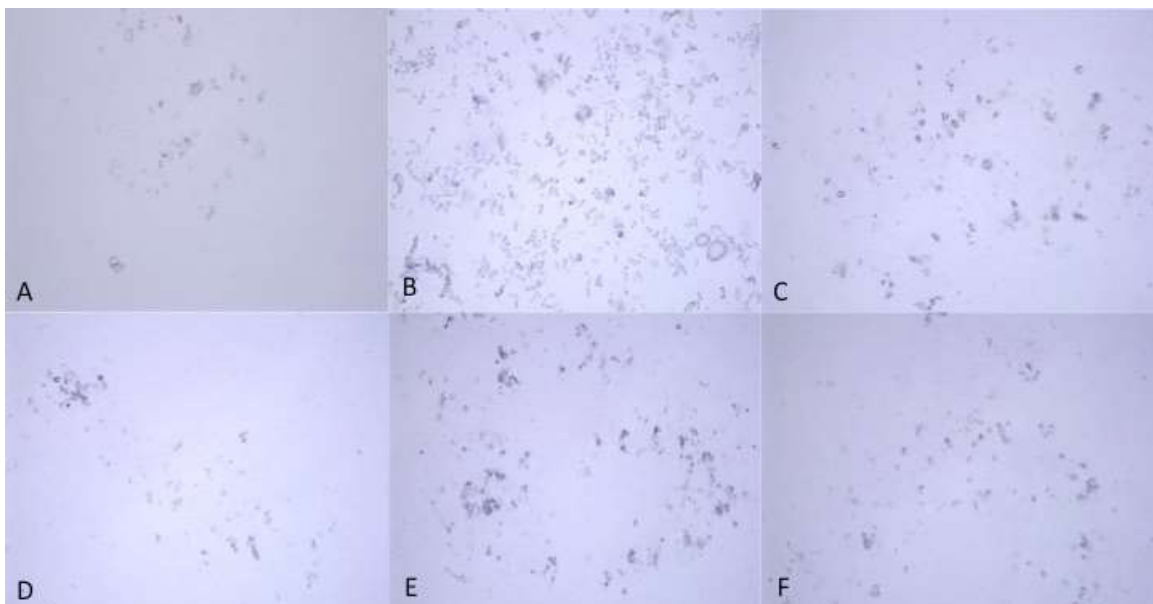


Figure 3: The crystal formation was observed with a light microscope at the end of the experiment (40X). [A] The sham group showed no crystal formation. [B] The vehicle sham group showed extensive amount of crystal formation. The crystals are larger in dimension, and the crystal nucleation was clearly visible. The amount of crystal present and nucleation in [C] AVCD_LD, [D] AVCD_HD, [E] GLBR_LD, and [F] GLBR_HD groups was lower in LD groups than HD and the sham group. AVCD and GLBR decreased the crystal nucleation and amount.

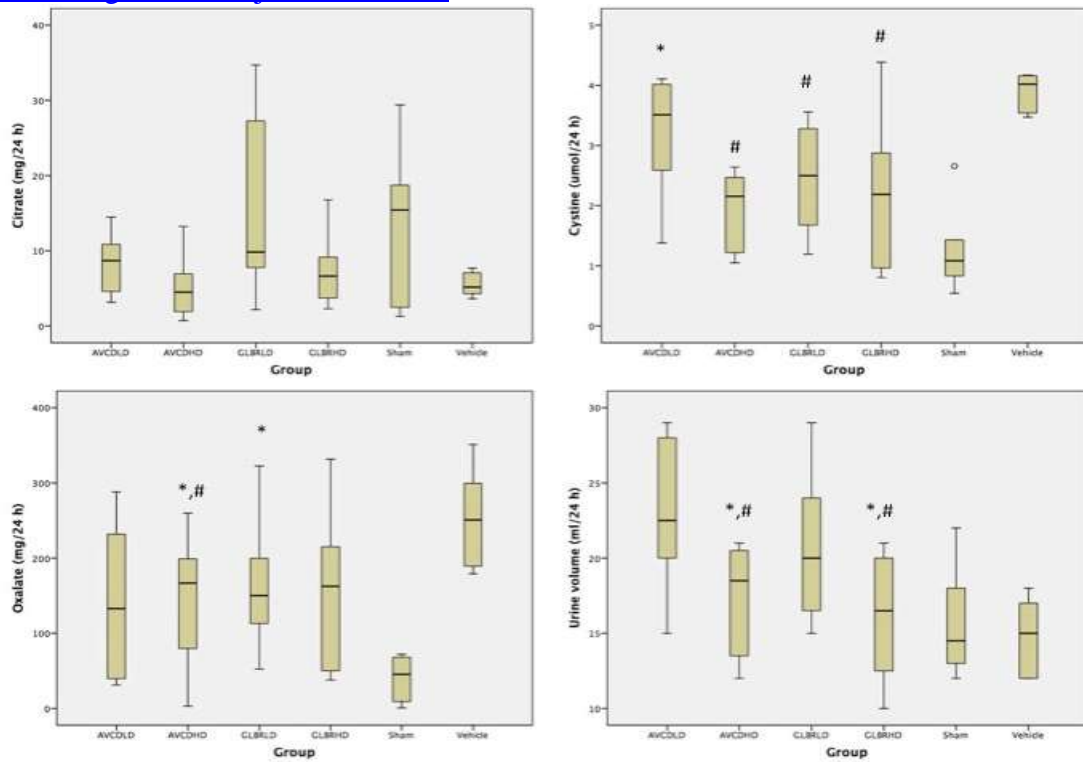


Figure 4: The cystine, oxalate, citrate levels and urine volume of the study groups. The symbols represent * : different from sham group, # : different from vehicle group.

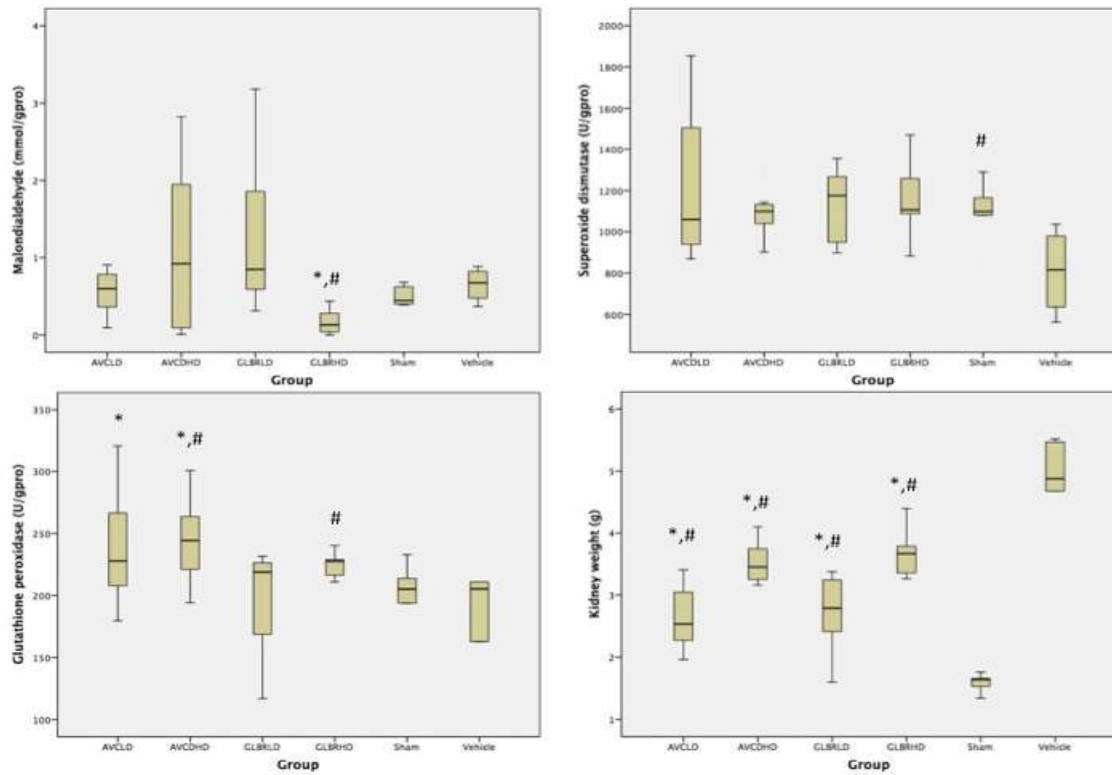


Figure 5: The kidney weight and antioxidant enzyme levels were represented. The symbols represent * : different from sham group, # : different from vehicle group.

<http://dx.doi.org/10.4314/ajtcam.v13i2.14>

Table 1: The urine and serum parameters of the study and control groups

Urinary Parameters	AVCD_LD	AVCD_HD	GLBR_LD	GLBR_HD	Sham	Vehicle Control		p
Urine output (ml/24 h)	22.50 (15-29)	18.50 (12-21)	20.00 (15-29)	16.50 (10-21)	14.50 (12-22)	15.00 (12-18)	0.011 ^{&} 0.016 ^{..}	0.016 [£] 0.019 ^{***}
Calcium (mg/24 h)	1.66 (0.49-3.28)	1.57 (0.49-3.34)	2.28 (1.68-2.99)	1.07 (0.40-2.86)	1.27 (0.72-2.57)	2.01 (0.95-2.72)	0.02 [§]	
Uric acid (mg/24 h)	0.04 (0.00-0.30)	0.09 (0.00-0.14)	0.20 (0.09-0.52)	0.10 (0.00-0.20)	0.12 (0.00-0.22)	0.90 (0.28-1.44)	0.03 [#] 0.02 ^{**} 0.12 ^{\$\$\$}	0.002 ^{***} 0.004 ^{****}
Phosphate (mg/24 h)	0.15 (0.05-1.70)	0.21 (0.02-0.39)	0.24 (0.03-1.18)	0.89 (0.10-6.42)	0.14 (0.04-4.90)	3.08 (0.16-7.56)	>0.05	
Magnesium (mg/24 h)	2.63 (0.65-5.07)	2.68 (0.40-4.21)	4.38 (0.95-7.35)	0.28 (0.02-3.65)	1.92 (0.02-5.11)	1.59 (0.41-3.24)	0.022 ^{ss}	
Urea (g/24h)	957.47 (763.79-1199.79)	880.32 (665.34-1017.40)	1129.71 (875.57-1412.58)	999.02 (794.59-1162.00)	1027.82 (824.63-1244.95)	994.22 (879.44-11382.52)	>0.05	
Creatinine	8614.58 (6559.28-10272.08)	9635.60 (7770.36-10678.72)	7399.08 (4154.80-10227.88)	9162.66 (8017.88-10855.52)	9984.78 (7045.48-11730.68)	9149.40 (6497.40-10935.08)	0.032 [§] 0.07 [§]	0.02 [£]
Citrate (mg/24 h)	8.68 (3.15-14.48)	4.51 (0.71-13.24)	9.80 (2.17-61.10)	6.63 (2.29-16.77)	15.42 (1.28-29.40)	5.15 (3.63-7.70)	>0.05	
Oxalate (mg/24 h)	132.80 (31.00-288.06)	166.74 (3.10-259.80)	150.15 (52.42-322.50)	162.50 (37.99-331.53)	45.50 (0.73-72.12)	250.85 (179.29-351.12)	0.02 ^{&} 0.043 ^{**}	0.005 [§]
Cystine (umol/24 h)	3.51 (1.38-8.20)	2.15 (1.05-11.31)	2.49 (1.19-8.52)	2.18 (0.81-4.39)	1.08 (0.54-2.66)	4.02 (3.47-4.17)	0.005 [*] 0.02 ^{**}	0.035 ^{ss} 0.029 ^{***}
Serum parameters								
Urea (mg/dl)	41.5 (36.00-52.00)	47.00 (38.00-61.00)	55.00 (44.00-68.00)	42.00 (38.00-62.00)	68.00 (62.00-77.00)	47.00 (39.00-51.00)	0.002 ^{*0.} 0.020 ^{&0.02} §	0.03 ^{ss} 0.002 [£] 0.006 ^{****}
Creatinine (mg/dl)	0.42 (0.37-0.48)	0.51 (0.35-0.63)	0.54 (0.48-0.59)	0.42 (0.37-0.47)	0.47 (0.38-0.55)	0.41 (0.35-0.52)	0.002 [*] 0.020 ^{&}	0.021 [§] 0.012 ^{ss} 0.045 [£]
Calcium (mg/dl)	8.89 (8.25-9.58)	9.36 (7.58-9.76)	9.59 (9.04-9.81)	9.17 (6.96-10.28)	9.24 (7.93-9.79)	9.59 (8.49-10.50)	>0.05	
Phosphorus (mg/dL)	4.88 (2.62-7.07)	6.92 (3.73-9.25)	6.62 (5.80-9.08)	6.47 (4.43-7.78)	5.54 (4.37-6.01)	6.24 (4.41-8.00)	0.028 [#] 0.007 [§]	
Magnesium (mg/dl)	2.24 (1.85-2.46)	2.58 (1.87-2.86)	2.48 (2.11-2.69)	2.39 (1.73-2.67)	2.28 (2.20-2.44)	2.24 (1.72-2.60)	>0.05	

Abbreviations: LD: Low dose, HD: High dose, ALT: alanine aminotransferase AST: aspartate aminotransferase, Na: Sodium, K: Potassium *1-5, #1-6, &2-5, **2-6, §3-5, ss3-6, £4-5, ****4-6, *****5-6

Table 2: Kidney weight and antioxidant enzyme levels of the kidney tissue

Kidney Parameters	AVCD_LD	AVCD_HD	GLBR_LD	GLBR_HD	Sham	Vehicle control	p
Kidney weight (gm)	2.53 (1.96-3.41)	3.45 (3.16-4.10)	2.79 (1.60-3.38)	3.67 (2.38-4.40)	1.65 (1.34-3.58)	4.88 (3.49-5.52)	<0.05 ψ <0.05 Φ
MDA (mmol/gpro)	0.599 (0.94-0.906)	0.92 (0.01-2.82)	0.848 (0.311-3.182)	0.130 (0.0-0.438)	0.445 (0.387-0.682)	0.762 (0.368-1.544)	0.007 [£] 0.007 ^{***}
SOD (U/gpro)	1059.2 (869.2-1853.8)	1100.2 (901.6-1302.3)	1176.5 (897.5-2671.1)	1107.2 (882.5-1469.4)	1099.1 (845.1 -1290.8)	815.75 (562.2-1036.0)	0.038 ^{**}
GPx (U/gpro)	227.8 (179.7-320.9)	244.4 (194.2-300.8)	218.9 (116.9-448.2)	227.6 (211.0-240.4)	205.2 (157.1 -233.0)	205.4 (89.9-211.2)	0.04 [#] 0.028 [§] 0.013 ^{**} 0.021 ^{***}

MDA: malondialdehyde, SOD: Superoxide dismutase, GSH: reduced glutathione, Φ for all sham group comparisons ψ for all vehicle group comparisons, *1-5, #1-6, &2-5, **2-6, §3-5, ^{§§}3-6, [£]4-5, ^{***}4-6, ^{****}5-6

Table 3: Histologic scoring of study groups.

Group	Glomerular changes						Mean Score	Tubular changes						Mean Score	Interstitial changes				Mean Score	Vascular changes			Mean Score	Total Mean Score			
	Congestion	Hemorrhage	Necrosis (mesangiolysis)	Intra-capillary proliferation	Extra-capillary proliferation (crescent formation)	Mesangial proliferation		Vacuolar degeneration	Necrosis	Epithelial flattening	Casts		Regeneration		Crystal deposition	Mean Score	Edema	Congestion		Hemorrhage	Inflammation	Mean Score			Vasculitis	Fibrinoid necrosis	Fibrintimal thickening
											Erythrocyte	Hyaline															
AVCD-HD	1	0	0	0	0	0	1	1.5	0	1.3	0	0.9	1	3	7.6	1.1	1.4	0	0.8	3.3	0	0	0	0	11.9*#		
AVCD-LD	1	0	0	0	0	0	1	1.5	0	1.1	0	1.1	0.4	2	6.1	1	1	0	0.3	2.3	0	0	0	0	9.4*#		
GLBR-HD	1	0	0	0	0	0	1	1	0	1	0	1.1	0.4	3	6.5	1	1	0	0.8	2.8	0	0	0	0	10.3*#		
GLBR-LD	1	0	0	0	0	0	1	1	0	1	0	1	0.7	2	5.7	1	1	0	0.7	2.7	0	0	0	0	9.4*#		
Sham	1	0	0	0	0	0	1	1	0	0	0	1	0	0	2	0.7	0.7	0	0.7	2	0	0	0	0	5.0*		
Vehicle Control	1	0	0	0	0	0	1	1	0	0	0	1	0	0	12.0	1	1	0	0.7	5.0	0	0	0	0	16.6#		
	0: Normal/No pathological changes 1: Focal* and segmental 2: Focal and global 3: Diffuse and segmental 4: Diffuse** and global *The involvement restricted in less than 50 % of glomeruli **The involvement restricted in more than 50 % of glomeruli						0: Normal/No pathological changes 1: Focal and mild 2: Focal and severe 3: Diffuse and mild 4: Diffuse and severe Scoring for crystal deposition: 0:<1; 1:<10; 2:<30; 3:<50; 4:<75 Scoring for casts: 0: No changes; 1:<25%; 2:26-50%; 3:51-75%; 4:>75						0: Normal/No pathological changes 1: Focal and mild 2: Focal and severe 3: Diffuse and mild 4: Diffuse and severe						0: Normal/No pathological changes 1: Minimal 2: Mild 3: Moderate 4: Severe								
*p<0.05 for sham group comparisons #p<0.05 for vehicle group comparisons & p<0.05 for LD and HD comparisons																											

References

1. Aggarwal KP, Narula S, Kakkar M, Tandon C. Nephrolithiasis: molecular mechanism of renal stone formation and the critical role played by modulators. *Biomed Res Int* Volume 2013 (2013); Article ID 292953. Epub: doi:10.1155/2013/292953
2. Butterweck V, Khan SR. (2009). Herbal medicines in the management of urolithiasis: Alternative or complementary? *Planta Med* 75:1095–1103.
3. Curhan GC. (2007). Epidemiology of stone disease. *Urol Clin North Am*, August; 34(3): 287–293. doi:10.1016/j.ucl.2007.04.003
4. Lieske JC, Leonard R, Toback FG. (1995). Adhesion of calcium oxalate monohydrate crystals to renal epithelial cells is inhibited by specific anions. *Am J Physiol* 268 (4): 604–612.
5. Marangella M, Vitale C, Bagnis C, Petrarulo M, Tricerri A. (2008). Use of drugs for nephrolithiasis. *Clin Cases Miner Bone* 5(2):131–134.
6. Nizami AN, Rahman MA, Ahmed NU, Islam MS. (2012). Whole *Leea macrophylla* ethanolic extract normalizes kidney deposits and recovers renal impairments in an ethylene glycol-induced urolithiasis model of rats. *Asian Pac J Trop Med*, July; 5(7): 533–538. doi:10.1016/S1995-7645(12)60094-7
7. Nouvenne A, Meschi T, Guerra A, Allegri F, Prati B, Borghi L. (2008). Dietary treatment of nephrolithiasis. *Clin Cases Miner Bone* 5(2):135–141.
8. Okhawa H, Ohshi N, Yagi K. (1979). Assay of lipid peroxides in animal tissues by thiobarbituric acid reaction. *Anal Biochem* 95: 351–358.
9. Paglia DE, Valentine WN. (1967). Studies on the quantitative and qualitative characterization of erythrocyte glutathione peroxidase. *J Lab Clin Med* 70: 158–169.
10. Patel PK, Patel MA, Saralai MG, Gandhi TR. (2012a). Antiurolithiatic effects of *Solanum xanthocarpum* fruit extract on ethylene-glycol-induced nephrolithiasis in rats. *J Young Pharm* 2012a, July-September; 4(3): 164–170.
11. Patel PK, Patel MA, Vyas BA, Shah DR, Gandhi TR. (2012b). Antiurolithiatic activity of saponin rich fraction from the fruits of *Solanum xanthocarpum* Schrad. & Wendl. (Solanaceae) against ethylene glycol induced urolithiasis in rats. *J Ethnopharmacol* October 31; 144(1): 160–70.
12. Pearle MS, Goldfarb DS, Assimos DG, Curhan GC, Denu-Ciocca CJ, Matlaga BR, Monga M, Penniston KL, Preminger GM, Turk TM, White JR (2014a). Medical management of kidney stones: AUA guideline. *J Urol*; 192: 316–324.
13. Pearle MS, Goldfarb DS, Assimos DG, Curhan GC, Denu-Ciocca CJ, Matlaga BR, , Monga M, Penniston KL, Preminger GM, Turk TM, White JR. (2014b). Medical management of kidney stones, AUA Guideline; Approved by the AUA Board of Directors, the American Urological Association. 2014b.
14. Qaseem A, Dallas P, Forciea MA, Starkey M, Denberg TD. (2014). Dietary and pharmacologic management to prevent recurrent nephrolithiasis in adults: A clinical practice guideline from the American College of Physicians. *Ann Intern Med* 161: 659–667. doi:10.7326/M13-2908
15. Sun Y, Oberley LW, Ying L. A simple method for clinical assay of superoxide dismutase. *Clin Chem* 1988; 34: 497–500.
16. Türk C, Knoll T, Petrik A, Sarica K, Skolarikos A, Straub M, Seitz C. (2014). European Association of Urology, Guidelines on Urolithiasis, 2014; 24–40.
17. Xu H, Zisman AL, Coe FL, Worcester EM. (2013). Kidney stones: An update on current pharmacological management and future