

Zhengyi Shao*

Department of Emergency, Beijing Tongren hospital, Affiliated to the Capital Medical University Beijing 100176, China.

Corresponding author Email: zhengyishao@hotmail.com

Abstract

Background: The present study evaluates the effect of *Spatholobus suberectus* stem extract (SS) in the management of pancreatitis alone and in combination with heparin.

Material and methods: Pancreatitis was induced pancreatitis by cerulean (50µg/kg, i.p.) five times at an interval of 1 h without any pretreatment of drug. Rats were treated with SS (100 and 200 mg/kg, p. o.) and heparin (150 U/kg, i.p.) alone and in combination for the duration of a week. Later pancreatic weight and blood flow was estimated and different biochemical parameters like concentration of D-dimer and Interleukin 1β (IL-1β) and activity of amylase and lipase were determined in blood of pancreatitis rats. Moreover effect of drug treatment on DNA synthesis and histopathology was also estimated on cerulean induced pancreatitis rats.

Result: Results of this study suggest that treatment with SS alone and in combination with heparin significantly increase in prothrombin time and pancreatic blood flow than negative control group. There was significant decrease in concentration of IL-1β and D-dimer and activity of amylase and lipase in SS and heparin treated group than negative control group. Pancreatic DNA synthesis was also found to be reduced in SS and heparin alone and in combination treated group. Histopathology study also reveals that treatment with SS and heparin alone and in combination reduces edema, hemorrhages, leukocyte infiltration in the TS of pancreatic tissues. **Conclusion:** Present study concludes that treatment with SS alone effectively manages the pancreatitis by ceasing the inflammatory pathway and potentiates the effect of heparin in the management of pancreatitis.

Keywords: *Spatholobus suberectus*, Pancreatitis, Heparin, Cerulean.

Introduction

Pancreatitis is a coagulation-like disorder. However, inflammation and coagulation is closely related to each other. Coagulation is induced by inflammation and activation of process of inflammation equally responsible for the coagulation as thrombosis (Levi et al, 2012). Reported study suggested that disturbance in microcirculation results in formation of pro-inflammatory cytokines; oxygen derived free radicals, release of proteolytic enzyme and activation of leukocytes (Salomone et al, 2003). Thrombin forms as inflammatory cytokines enhances the expression of tissue factor on endothelium and monocytes (Maeda et al, 2006).

Reported study suggested that heparin/anticoagulant shows protective effect in pancreatitis in animal as well as clinical study. Pretreatment with heparin ceases the development of pancreatitis induced by cerulean, taurocholate and bile on various animal studies (Gabryelewicz et al, 1969). Moreover heparin restores the pancreatic function in cerulean induced pancreatitis if it is administered after the induction of pancreatitis (Dobosz et al, 1998; Qiu et al, 2007). Moreover a study suggested that heparin manages the hyperlipidemia induced pancreatitis when co administered with insulin and in sever pancreatitis it protects the encephalopathy (Alagözlü et al, 2006; Kyriakidis et al, 2006). Heparin manages the pancreatitis by inhibiting the formation of thrombin through heparin-antithrombin III complex (Warzecha et al, 2010). However, effect of heparin over inflammatory parameters or pathway is not given in the literatures.

Spatholobus suberectus belongs to family: Leguminosae used for the management of several disorders such as rheumatism, anemia and abnormal menstruation traditionally in China (Lam et al, 2000; Li et al, 2003; Yen, 1992). Reported study suggested that several compounds like butin, liquiritigenin, dihydroquercetin, plathymenin, eriodictyol and neoisoliquiritigenin were been isolated from stem of SS (Lee et al, 2006). A study on stem extract of SS effectively manages cerebral ischemia by attenuating NF-κB p65 and cytokines and thereby prevents the DNA damage (Zhang et al, 2016). Moreover studies like anti rheumatic, anti inflammatory, antioxidant and anti platelet activity of SS are reported in the literature (Zhang et al, 2016). Thus this study evaluates the synergistic effect of *Spatholobus suberectus* extract when treated with heparin in pancreatitis.

Material and Methods

Animals

Healthy male Wistar rats of 180-200 g body weight were used for the pharmacological screening in the present study. The animals were housed at $25 \pm 2^\circ\text{C}$ temperature, 12 h light/dark cycle and $60 \pm 5\%$ of relative humidity. Rats were fed with standard diet and water ad libitum. Protocols of the present investigation for all the animal studies were approved by Capital University of Medical Science, Beijing.

Plant Extract

Spatholobus suberectus was procured from the local botanist. *S. suberectus* stem cut into small pieces and dried it under the shade. Later it was boiled for specific duration of time in distilled water and then filters the extract by using filter paper (150 μm). Thereafter the extract was lyophilized. During the experiment at the time of dosing extract of SS was dissolved in distilled H_2O and for 5 min centrifuge it at 10000 RPM.

Induction of Pancreatitis

All the rats were separated in to seven different group (n=8) such as Control group which receives only saline; Negative control group which receives cerulean (50 $\mu\text{g}/\text{kg}$, i.p.) five times at an interval of 1 h without any pretreatment of drug; Heparin treated group receives 150 U/kg of heparin 1 day after the cerulean by subcutaneous injection twice a day; SS treated group receives 100 and 200 mg/kg of SS extract p. o. 1 day after the cerulean injection; Heparin +SS treated group receives heparin (150 U/kg, s. c.) and SS (100 and 200 mg/kg) 1 day after the cerulean injection for the duration of one week (Baczyńska et al, 2004).

Estimation of pancreatic blood flow

All the animals were anesthetized by ketamine (50mg/kg, i.p.) at the end of protocol and pancreatic blood flow was estimated as per previously reported methods in exposed pancreas by using a laser Doppler flowmeter. Interpretation of data was represented as percent change from value obtained in control group without induction of pancreatitis.

Estimation of Biochemical parameters

Later abdominal aorta was used for the collection of fresh blood sample and prothrombin time was estimated in it as international normalized ratio using test strip (Alere San Diego, Inc., USA). Immunoturbidimetric assay method was used for the estimation of concentration of plasma D-Dimer by using automatic coagulation analyzer (BCS XP System, Simens Healthcare Diagnostics, Germany). Kodak Ectachem DT II System analyzer was used for the estimation of activity of amylase and lipase in serum using Amyl and Lipa DT Slides. Interlukin 1β (IL- 1β) concentration was estimated in the serum by using IL- 1β Platinum Elisa (Konturek et al, 1994).

Estimation of pancreatic DNA synthesis

Pancreas isolated from all the rats was weighed. Later for histological examination and pancreatic DNA synthesis was done for the pancreatic tissue. Assessment of labeled thymidine in to DNA was done for the estimation of rate of pancreatic DNA synthesis as per previously reported study. Rate of DNA synthesis was expressed as disintegrations of labeled thymidine per minute per microgram DNA (dpm/ μg DNA) (Dembiński et al, 2006).

Histopathology study

Hematoxylin and eosin (H&E) staining was done for the examination of damage of pancreatic tissue as given in previous report. A scale of range from 0 to 3 was used for histological grading of necrosis, hemorrhages, vacuolization of acinar cells, leukocyte inflammatory infiltration and edema (Tomaszewska et al, 2000).

Statistical analysis

Data of present study given as mean \pm SD (n=8). Statistically analysis was done by one way ANOVA (Dunnett.) In this study values $p < 0.05$ was considered as significant.

Result

Effect of *Spatholobus suberectus* and heparin on prothrombin time, weight of pancreas and pancreatic blood flow

Effect of *Spatholobus suberectus* in combination with heparin was observed on prothrombin time in cerulean induced pancreatitis as shown in Figure 1. There was significant ($p < 0.05$, $p < 0.01$) increase in the prothrombin time in heparin, SS 100 & 200 mg, heparin+SS 100 mg/kg and heparin+SS 200 mg/kg treated group than negative control group.

Weight of pancreas was significantly increases in cerulean induced pancreatitis group i.e. negative control group than control group. It was also observed that treatment with *Spatholobus suberectus* and heparin alone and in combination significantly decreases ($p < 0.05$, $p < 0.01$) the weight of pancreas compared to negative control group (Figure2.). Moreover treatment with *Spatholobus suberectus* and heparin alone and in combination increases the pancreatic blood flow which is calculated as % of control group than negative control group (Figure3.).

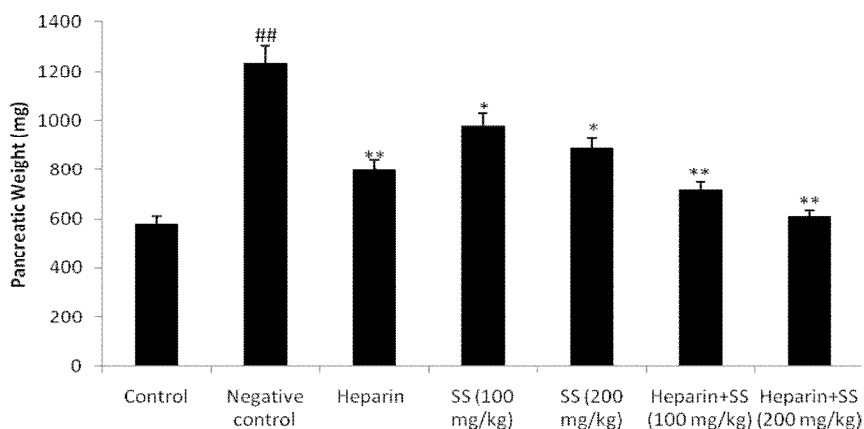


Figure 1: Effect of *Spatholobus suberectus* in combination with heparin was observed on prothrombin time as international normalized ratio (INR) in cerulean induced pancreatitis
Means \pm SD (n=8), ## $p < 0.01$ Vs control, * $p < 0.05$, ** $p < 0.01$ Vs Negative control

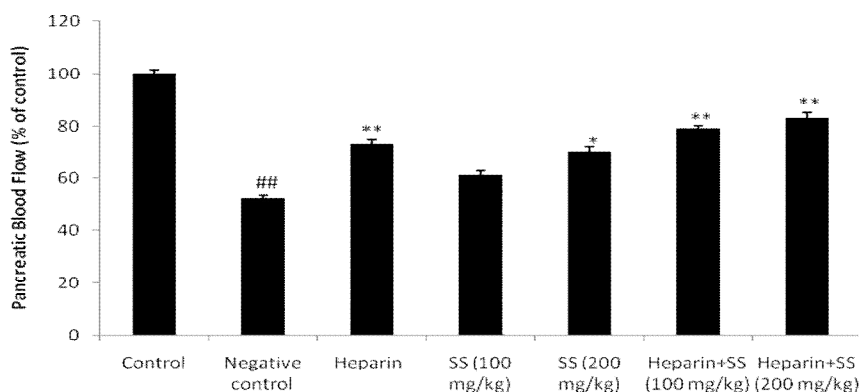


Figure 2: Effect of *Spatholobus suberectus* in combination with heparin was observed on pancreatic weight in cerulean induced pancreatitis
Means \pm SD (n=8), ## $p < 0.01$ Vs control, * $p < 0.05$, ** $p < 0.01$ Vs Negative control

Effect of *Spatholobus suberectus* and heparin on biochemical parameters

Effect of *Spatholobus suberectus* and heparin alone and in combination on the concentration of D-dimer in cerulean induced pancreatitis as shown Figure 4. It was observed that treatment with *Spatholobus suberectus* and

heparin alone and in combination significantly decreases the concentration of D-dimer in cerulean induced pancreatitis than negative control group.

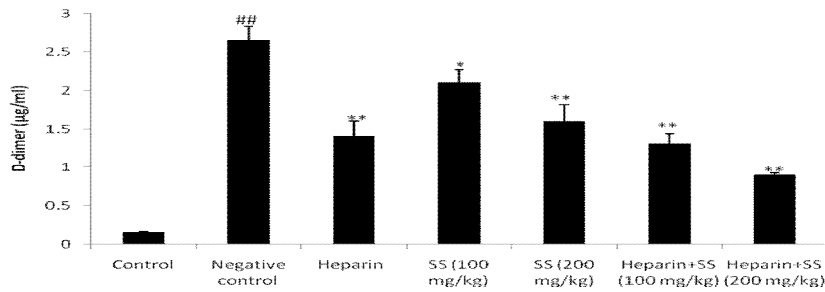


Figure 3: Effect of *Spatholobus suberectus* in combination with heparin was observed on pancreatic blood flow (% of control) in cerulean induced pancreatitis

Means ± SD (n=8), ^{###}p < 0.01 Vs control, *p<0.05, **p<0.01 Vs Negative control

In cerulean induced pancreatitis rats the activity of lipase and amylase enzyme and concentration of IL-1β significantly increases than control group. There were significant decrease in the activity of lipase and amylase enzyme and concentration of IL-1β in *Spatholobus suberectus* and heparin alone and in combination treated group of rats compared to negative control group as shown in Figure 5 a, b & c.

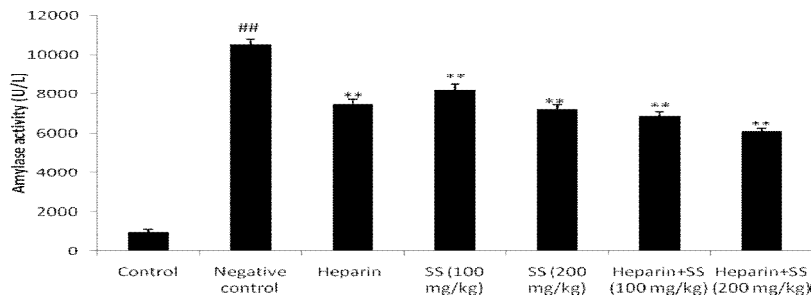
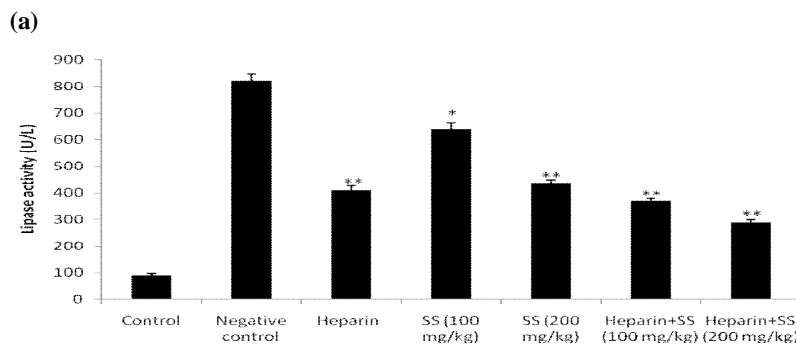


Figure 4: Effect of *Spatholobus suberectus* in combination with heparin was observed on the concentration of D-dimer in cerulean induced pancreatitis

Means ± SD (n=8), ^{###}p < 0.01 Vs control, *p<0.05, **p<0.01 Vs Negative control



(b)

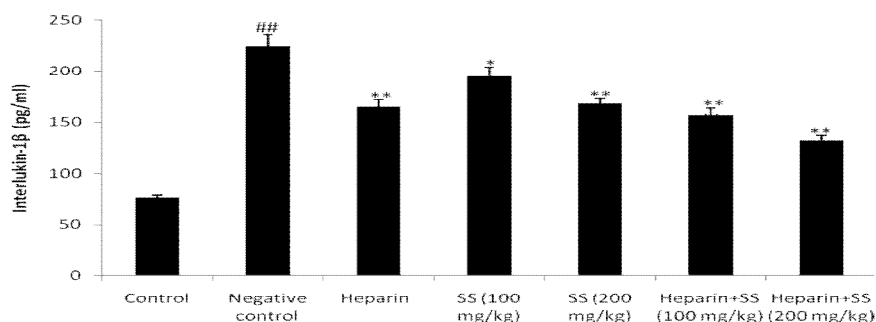


Figure 5: Effect of *Spatholobus suberectus* and heparin on biochemical parameter in cerulean induced pancreatitis. (a) Amylase activity; (b) Lipase activity; (c) Interlukin 1β
Means ± SD (n=8), ^{###}p < 0.01 Vs control, *p<0.05, **p<0.01 Vs Negative control

Effect of *Spatholobus suberectus* and heparin on pancreatic DNA synthesis

Effect of *Spatholobus suberectus* and heparin alone and in combination on pancreatic DNA synthesis was shown in Figure 6. There were significant (p<0.05, p<0.01) increase in the pancreatic DNA synthesis in *Spatholobus suberectus* and heparin alone and in combination treated group of rats compared to negative control group as shown in Figure 6.

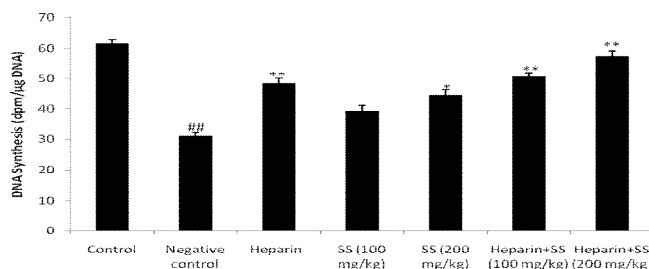


Figure 6: Effect of *Spatholobus suberectus* and heparin on pancreatic DNA synthesis in cerulean induced pancreatitis. Means ± SD (n=8), ^{###}p < 0.01 Vs control, *p<0.05, **p<0.01 Vs Negative control

Effect of *Spatholobus suberectus* and heparin on histopathology of pancreas

Histopathology study was performed on *Spatholobus suberectus* and heparin treated cerulean induced pancreatitis rats as shown in Table 1 and Figure 7. It was observed that pancreas of cerulean induced pancreatitis rats shows severe edema, moderate diffuse infiltration of inflammatory leukocyte and hemorrhages. Acinar cell shows more than 50% of vacuolization and signs of necrosis was absent in the TS of pancreas. Treatment with *Spatholobus suberectus* and heparin alone and in combination attenuates the development of pancreatitis. Histopathological representation shows that heparin in combination with SS significant decline in vacuolization of acinar cells, inflammatory infiltration and pancreatic edema.

Table 1: Effect of *Spatholobus suberectus* and heparin on histopathology signs of pancreas

Sr. No.	Group	Edema (0-3)	Inflammatory Infiltration (0-3)	Vacuolization (0-3)	Necrosis (0-3)	Hemorrhages (0-3)
1	Control	0	0	0	0	0
2	Negative control	2-3	1-2	2-3	0	1-2
3	Heparin	0-1	0-1	0	0	0
4	SS (100 mg/kg)	1-2	0-1	0-1	0	0-1
5	SS (200 mg/kg)	0-1	0	0	0	0-1
6	Heparin+SS(100 mg/kg)	0-1	0-1	0	0	0-1
7	Heparin+SS (200 mg/kg)	0-1	0	0	0	0

Discussion

Heparin reported to have beneficial effect on pancreatitis. Heparin manages the pancreatitis by inhibiting the formation of thrombin through heparin-antithrombin III complex but its effect over inflammatory pathway is not evaluated yet (Warzecha et al, 2010). Moreover *Spatholobus suberectus* reported to possess anti-inflammatory, antioxidant and anti-platelet activity (Zhang et al, 2016). Thus an attempt was made to evaluate the beneficial effect of *Spatholobus suberectus* in cerulean induced pancreatitis and synergistic effect of SS with heparin in cerulean induced pancreatitis rat model. It was evaluated by estimating the prothrombin time, pancreatic weight and blood flow in cerulean induced pancreatitis. Biochemical parameters such as concentration of IL-1 β , D-dimer, activity of amylase and lipase and DAN synthesis was estimated in cerulean induced pancreatitis rat model. Moreover histopathology study was also performed.

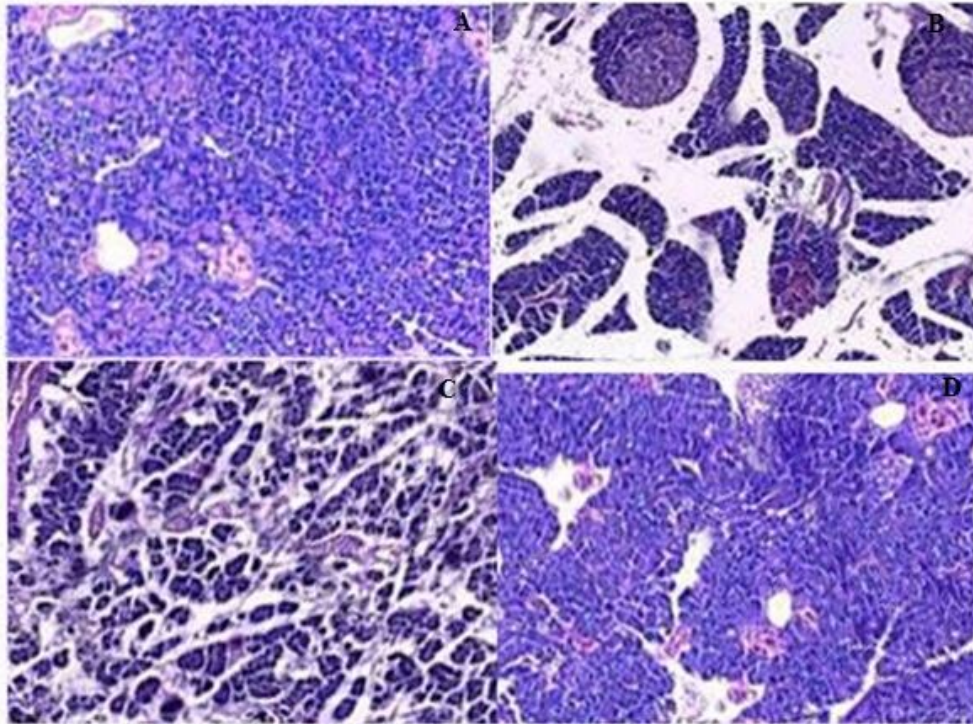


Figure 7: Effect of drug treatment on histopathology of pancreatic tissue in cerulean induced pancreatitis rat model. A. Control; B. Negative control; C. SS 200 mg/kg; D. Heparin+SS 200 mg/kg.

The result of the given study suggested that SS alone and in combination with heparin significantly increase in the prothrombin time and pancreatic blood flow in cerulean induced pancreatitis rat model. Literature suggested that in pancreatitis, pancreatic blood flow and prothrombin time significantly decreases and the anticoagulants reported to enhance the blood flow and thereby effectively manage the pancreatitis (Ceranowicz et al, 2015).

There is activation of leukocyte which results in inflammatory cytokines release that develops the inflammation in pancreatitis. In pancreatitis cytokines like IL-1 β is responsible for inflammatory response and activates the prostaglandin, platelet activating factor and TNF α . These mediators cease the synthesis of DNA and thereby do damage to the pancreatic cells (Fink and Norman, 1996; Vollmar and Menger, 2003). Histopathology of pancreatic tissue reveals the presence of edema, leukocyte infiltration, hemorrhages and vacuolization in pancreatitis.

The investigation reveals that SS alone and in presence of heparin effectively decreases the concentration of IL1 β , D-dimer in blood and activity of amylase and lipase than negative control group. Moreover SS alone and in combination with heparin reduces the DNA synthesis in pancreatitis rats. Effect of SS and heparin alone and in combination on histopathology of pancreas tissue attenuates the pancreatitis by reducing the edema, hemorrhages and leukocyte infiltration.

Conclusion

Present study concludes that treatment with SS alone effectively manages the pancreatitis by ceasing the inflammatory pathway. Moreover SS in combination with heparin gives synergistic effect as in combination it act on inflammatory and coagulation pathway simultaneously for the pancreatitis.

Acknowledgement

Author of this manuscript thankful to department of emergency, affiliated Beijing Tongren hospital, Capital University of Medical Science, China, for providing necessary facility for this work.

References

1. Alagözülü, H.; Cindoruk, M.; Karakanm, T.; Unal, S. Heparin and insulin in the treatment of hypertriglyceridemia-induced severe acute pancreatitis. *Dig. Dis. Sci.* **2006**; 51: 931–933.
2. Baczyńska, A. Doustne leki przeciwkrzepliwe w różnych stanach klinicznych—Praktyczny poradnik. *Chor. Serca Naczyn* **2004**; 1: 27–36.
3. Ceranowicz, P.; Cieszkowski, J.; Warzecha, Z.; Dembiński, A. Experimental models of acute pancreatitis. *Postepy Hig. Med. Dos.* **2015**; 69: 264–269.
4. Dembiński, A.; Warzecha, Z.; Ceranowicz, P.; Dembiński, M.; Cieszkowski, J.; Pawlik, W.W.; Tomaszewska, R.; Konturek, S.J.; Konturek, P.C. Effect of ischemic preconditioning on pancreatic regeneration and pancreatic expression of vascular endothelial growth factor and platelet-derived growth factor-A in ischemia/reperfusion-induced pancreatitis. *J. Physiol. Pharmacol.* **2006**; 57: 39–58.
5. Dobosz, M.; Wajda, Z.; Hac, S.; Mysliwska, J.; Mionskowska, L.; Bryl, E.; Roszkiewicz, A.; Mysliwski, A. Heparin and nitric oxide treatment in experimental acute pancreatitis in rats. *Forum (Genova)* **1998**; 8: 303–310.
6. Fink, G.W.; Norman, J.G. Intrapancreatic interleukin-1_α gene expression by specific leukocyte populations during acute pancreatitis. *J. Surg. Res.* **1996**; 63: 369–373.
7. Gabryelewicz, A.; Niewiarowski, S.; Prokopowicz, J.; Chlebowski, J. Heparin and protease inhibitors in the prevention of experimental acute pancreatic necrosis in dogs. *Digestion* **1969**; 2: 7–16.
8. Konturek, S.J.; Szlachcic, A.; Dembinski, A.; Warzecha, Z.; Jaworek, J.; Stachura, J. Nitric oxide in pancreatic secretion and hormone-induced pancreatitis in rats. *Int. J. Pancreatol.* **1994**; 15: 19–28.
9. Kyriakidis, A.V.; Raitsiou, B.; Sakagianni, A.; Harisopoulou, V.; Pyrgioti, M.; Panagopoulou, A.; Vasilakis, N.; Lambropoulos, S. Management of acute severe hyperlipidemic pancreatitis. *Digestion* **2006**; 73: 259–264.
10. Lam, T.L., Lam, M.L., Au, T.K., Ip, D.T., Ng, T.B., Fong, W.P., Wan, D.C., A comparison of human immunodeficiency virus type-1 protease inhibition activities by the aqueous and methanol extracts of Chinese medicinal herbs. *Life Sciences* **2000**; 67: 2889–2896.
11. Lee MH, Lin YP, Hsu FL, Zhan GR, Yen KY. Bioactive constituents of *Spatholobus suberectus* in regulating tyrosinase-related proteins and mRNA in HEMn cells. *Phytochemistry*. **2006**; 67(12):1262-70.
12. Levi, M.; van der Poll, T.; Schultz, M. New insights into pathways that determine the link between infection and thrombosis. *Neth. J. Med.* **2012**; 70: 114–120.
13. Li, R.W., David Lin, G., Myers, S.P., Leach, D.N., Antiinflammatory activity of Chinese medicinal vine plants. *Journal of Ethnopharmacology* **2003**; 85: 61–67.
14. Maeda, K.; Hirota, M.; Ichihara, A.; Ohmuraya, M.; Hashimoto, D.; Sugita, H.; Takamori, H.; Kanemitsu, K.; Baba, H. Applicability of disseminated intravascular coagulation parameters in the assessment of the severity of acute pancreatitis. *Pancreas* **2006**; 32: 87–92.
15. Qiu, F.; Lu, X.S.; Huang, Y.K. Effect of low molecular weight heparin on pancreatic micro-circulation in severe acute pancreatitis in a rodent model. *Chin. Med. J.* **2007**; 120: 2260–2263.
16. Salomone, T.; Tosi, P.; Palareti, G.; Tomassetti, P.; Migliori, M.; Guariento, A.; Saieva, C.; Raiti, C.; Romboli, M.; Gullo, L. Coagulative disorders in human acute pancreatitis: Role for the D-dimer. *Pancreas* **2003**; 26: 111–116.
17. Tomaszewska, R.; Dembiński, A.; Warzecha, Z.; Ceranowicz, P.; Stachura, J. Morphological changes and morphological-functional correlations in acute experimental ischemia/reperfusion pancreatitis in rats. *Pol. J. Pathol.* **2000**; 51: 179–184.
18. Vollmar, B.; Menger, M.D. Microcirculatory dysfunction in acute pancreatitis. A new concept of pathogenesis involving vasomotion-associated arteriolar constriction and dilation. *Pancreatology* **2003**; 3: 181–190.
19. Warzecha, Z.; Dembiński, M.; Ceranowicz, P.; Dembiński, A. Heparyna i jej działanie przeciwzapalne w przewodzie pokarmowym (Heparin and its anti-inflammatory action in the gut). *Gastroenterol. Pol.* **2010**; 17: 227–233.
20. Yen, K.Y., 1992. The illustrated Chinese materia medica. In: Yen, K.Y. (Ed.), *The Illustrated Chinese Materia Medica*. SMC Publishing Inc., Taipei.
21. Zhang R, Liu C, Liu X, and Guo Y. Protective effect of *Spatholobus suberectus* on brain tissues in cerebral ischemia. *Am J Transl Res.* **2016**; 8(9): 3963–3969.